

**Authors:** Ana Belén Márquez-Ruiz<sup>a</sup>, María Concepción Treviño-Tijerina<sup>b</sup>, Lucas González-Herrera<sup>a</sup>, Belén Sánchez<sup>a</sup>, Amanda Rocío González-Ramírez<sup>c</sup> and Aurora Valenzuela<sup>a</sup>

**Title:** Three-dimensional analysis of third molar development to estimate age of majority

<sup>a</sup> Department of Forensic Medicine, Faculty of Medicine, University of Granada, Avenida de la Investigación 11, 18016 Granada, Spain.

<sup>b</sup> Faculty of Odontology, Autonomous University of Nuevo Leon, Eduardo Aguirre Pequeño cruz con Silao, Colonia Mitras Centro, 64460 Monterrey, Nuevo Leon, Mexico.

<sup>c</sup> Biomedical Research Foundation of Eastern Andalusia (FIBAO), Biosanitary Institute of Granada (ibs.GRANADA), Calle Dr. Azpitarte 4, 18012 Granada, Spain.

**Corresponding author:** Ana Belén Márquez-Ruiz Email: [abmarquez@ugr.es](mailto:abmarquez@ugr.es)

**Abstract** Third molars are one of the few biological markers available for age estimation in undocumented juveniles close the legal age of majority, assuming an age of 18 years as the most frequent legal demarcation between child and adult status. To obtain more accurate visualization and evaluation of third molar mineralization patterns from computed tomography images, a new software application, DentaVol<sup>®</sup>, was developed. Third molar mineralization according to qualitative (Demirjian's maturational stage) and quantitative parameters (third molar volume) of dental development was assessed in multi-slice helical computed tomography images of both maxillary arches displayed by DentaVol<sup>®</sup> from 135 individuals (62 females and 73 males) aged between 14 and 23 years. Intra- and inter-observer agreement values were remarkably high for both evaluation procedures and for all third molars. A linear correlation between third molar mineralization and chronological age was found, with third molar maturity occurring earlier in males than in females. Assessment of dental development with both procedures, by using DentaVol<sup>®</sup> software, can be considered a good indicator of age of majority (18 years or older) in all third molars. Our results indicated that virtual computed tomography imaging can be considered a valid alternative to orthopantomography for evaluations of third molar mineralization, and therefore a complementary tool for determining the age of majority.

**Keywords** Age estimation · Third molar · Mineralization · Multi-slice computed tomography

## **1. Introduction**

An important emerging challenge in recent years for forensic practitioners around the world is age diagnosis in living persons. The increasing numbers of undocumented individuals moving across international borders has led to growing pressure from legal systems to provide more accurate age estimates. In many countries the legal age limit is between 14 and 21 years, with age 18 years being the most frequent legal demarcation between child and adult status [1–4].

Several methods have been recommended for forensic age diagnosis in criminal, civil and asylum proceedings to determine whether an individual has reached the age of majority when the date at birth is uncertain [1,5]. These methods include physical examination, determination of anthropometric measures and evidence of sexual maturation stage, radiographic examination of the left hand, and dental examination including orthopantomography (OPG). If skeletal development of the hand is complete, additional X-ray examination of the clavicles should be used [6–9]. All recommended procedures should be used in combination to increase diagnostic accuracy and improve the likelihood of identifying any age-relevant developmental disorders [5,6,10,11].

In dental examinations, dental mineralization and eruption are the two main parameters used in forensic age estimation from birth to adulthood. Dental mineralization comprises a more uniform and continuous set of changes than eruption, and may be less influenced by external factors compared to other measurable criteria of maturity [5,12]. In addition, dental mineralization is slower and delayed compared to skeletal bone [13], and correlates with different morphological stages of mineralization that can be determined by evaluating dental X-rays [14]. For these reasons, several methods have been proposed to define distinct dental mineralization stages [15–17]. However, age estimation becomes more complicated in individuals aged 14 years or older because most teeth are fully developed, and the only teeth still growing are the third molars [18]. Despite their highly variable patterns of formation (agenesis is frequent and the age of complete mineralization varies widely), third molars are one of the few sources of useful data to estimate biological age in young persons near the legal age of majority, in the absence of better dental indicators. This makes the study of third molars, in conjunction with skeletal maturity, an appropriate method for estimating the age of undocumented juveniles or asylum seekers [19]. Among the numerous methods

developed to evaluate third molar maturation [20–23], the scoring system of Demirjian et al. appears to be the most reliable in terms of both observer agreement and the correlation between stages [17–19,24–30].

Nevertheless, the methods proposed thus far to assess third molar mineralization are usually based on the evaluation of an OPG, a two-dimensional panoramic radiograph of both maxillary arches [17–19,24–30]. Therefore, when bone structures or teeth overlap, roots cannot be clearly visualized, and it is enormously difficult to discern differences between two consecutive maturational stages. Because of these difficulties, alternative imaging modalities such as computed tomography (CT) and magnetic resonance imaging (MRI) are making inroads into medicolegal age estimation [31–38]. In connection with dental age estimation, it has been shown that CT scans cause no magnification errors due to geometric distortion, which is a common problem in conventional radiography. In addition, CT scans are able to provide accurate, measurable three-dimensional (3D) images of the third molar that can be rotated in space [39–42], which facilitates assignment of the correct mineralization stage.

To achieve more accurate visualization and assessment of third molar mineralization from multi-slice helical CT (MSCT) images, we developed a new computer forensic analysis tool called DentaVol<sup>®</sup>. This tool makes it possible to isolate a 3D image of a third molar from adjacent and superimposed mineralized structures, in order to study qualitative and quantitative parameters of dental development such as maturational stage and third molar volume. Therefore, the aims of this study were (1) to determine third molar maturational stages according to Demirjian's schemes from MSCT images displayed by DentaVol<sup>®</sup> in a population sample of individuals of known chronological age, (2) to measure third molar volumes using DentaVol<sup>®</sup> in the same sample, and (3) to evaluate the accuracy of each procedure to assess third molar development in order to identify individuals 18 years of age or older.

## **2. Materials and methods**

### **2.1. Sample**

The sample consisted of MSCT images of 230 maxillary third molars and 230 mandibular third molars from 135 individuals aged between 14 and 23 years (62 females, age range: 14.00-22.92, mean: 18.23; 73 males, age range: 14.00-22.83, mean 17.98), collected retrospectively from the database of the Diagnostic and Image Center

of University Hospital Dr. Eleuterio González, Autonomous University of Nuevo Leon (AUNL) in Monterrey, Mexico. An additional sample of MSCT images from 30 individuals aged between 14 and 23 years (12 females, mean age: 18.25; 18 males, mean age: 17.00) collected retrospectively from the databases of different private dental clinics in Cordoba, Spain, was used to validate the method. A multi-slice helical high-resolution LightSpeed® VCT CT system (General Electric Healthcare, Chicago, IL, USA) was used, and files were collected in Digital Imaging and Communication in Medicine (DICOM) format. MSCT scans were excluded if all third molars were missing or if image deformity affected the area of interest. Each image was labelled with a random number to blind the observers to the patient's name, sex, date of birth and date of the MSCT image, which were recorded. Chronological age for each case was calculated from the date of birth and the date of the MSCT image. The protocols to collect human MSCT images were approved by the Ethic Committees of AUNL University Hospital and the University of Cordoba, and the study was conducted in accordance with the ethical standards laid down by the Declaration of Helsinki. All participants voluntarily agreed to take part in the study and they, their parents or their legal representatives as appropriate signed an informed consent form.

## **2.2. The custom-made DentaVol® software for image analysis**

DentaVol® (2015, Department of Forensic Medicine, University of Granada, Granada, Spain) is a software tool designed and developed specifically for this study by the Computer Graphics Group of the Department of Computer Languages and Systems of the University of Granada (Dr. FJ Rodríguez-Prados and Prof. Dr. JC Torres-Cantero). DentaVol® is useful for the analysis of dental volumes constructed from CT images in DICOM format. The DentaVol® program creates 3D images from two-dimensional images. Pixels are the smallest components of a digital image, storing a value that represents the intensity of a given color in any specific area, but that together form a continuous image of the structure of interest. The program extends these pixels to the third dimension (voxels), which connect upper and lower sections to create a solid-appearing 3D image on the computer monitor. Each voxel has a shade of gray (colors ranging from white to black), length, height and width, and these properties allow the program to calculate distances between both breakpoints and volumes, or to select tissues with voxels of a given color (teeth are closer to white than soft tissues, which appear in darker shades).

The system is built on a sequence of processing steps which includes reading images in DICOM format, generating 3D models from the information contained in the images, 3D displays for these models, selection of specific areas within the full model (submodels), and distance and volume measurements in the 3D model as a whole or in specific parts (isolated teeth). The DentaVol<sup>®</sup> interface consists of four elements as shown in Figure 1. (1) The *toolbar* includes several tools to accurately select the area of study (e.g. a wisdom tooth). (2) The *display area* (central area of the interface) shows 3D models that can be rotated. (3) The *grayscale filter* shows a shade of gray that allows the user to select the desired voxels. (4) The *case study data area* shows the different measurement data. Figure 1 also shows the processing procedures to construct the final 3D image of each isolated area in the following steps:

a. *Visualization of the 3D model from the CT image.*

b. *Selection of the area of interest.* To obtain a usable display of the tooth of interest, voxels representing non-dental tissues can be removed with the display filter. In addition, clicking on the image with the cursor activates trackball rotation of the 3D model in any direction to choose the most convenient angle to select the area where the third molar is located, using the *tooth selection tool* (1A). The result is an image in which only the selected teeth are shown.

c. *Isolation of the third molar.* By clicking on the third molar, the *clean* tool (1B) allows the user to separate it from adjacent teeth. In most cases, when the third molar is in contact with the second molar, the wisdom tooth needs to be isolated with the *eraser* tool (1C), which allows the user to manually delete the line joining the two teeth. At this time the image can be easily rotated to facilitate visualization of the third molars roots.

d. *Volume measurements.* Once the 3D image of the third molar has been isolated, volume measurements in cubic millimeters can be obtained and exported automatically to a case study data table, first by creating the data table and then by clicking on the corresponding cell in the *Volume* row in the table.

The computer hardware used with this program includes an Intel<sup>®</sup> Core<sup>™</sup> i7, 870 processor (Intel Corporation, Santa Clara, CA, USA) running at 2.93 GHz, with 8.00 GB RAM, and a Nvidia graphic card (Nvidia Corporation, Santa Clara, CA, USA), which produces high-quality, readily manipulable images of the 3D models generated by DentaVol<sup>®</sup>.

### **2.3. Assessment of third molar mineralization according to Demirjian's stages**

From 3D images of the third molars displayed by DentaVol<sup>®</sup>, we evaluated the mineralization stage of each third molar according to the mineralization scheme proposed by Demirjian et al. [21] and adapted by Mincer et al. [20], as applied in previous studies [17–19,24,25,28,29]. This system is based on eight stages of tooth formation ranging from the beginning of cusp calcification (stage A) to root apex closure (stage H). Figure 2 illustrates the eight-stage classification of tooth mineralization proposed by Demirjian compared to 3D images obtained from DentaVol<sup>®</sup> for each stage.

*Stage A:* The beginning of cusp calcification is visible as inverted cones. *Stage B:* The occlusal surface of the molar is visible as a result of fusion of the calcification points.

*Stage C:* The occlusal surface spreads and converges toward the cervical region.

*Stage D:* Crown formation is complete down to the cementum-enamel junction (CEJ). A spicule is seen, indicating the beginning of root formation.

*Stage E:* Initial inter-radicular bifurcation appears in the form of a calcified dot or semilunar shape. The root is still shorter than the crown.

*Stage F:* The root has developed further down the bifurcation, showing funnel-shaped endings. Root length is equal to or longer than crown length.

*Stage G:* The walls of the root canals are parallel. The root apices are partially open.

*Stage H:* Apex closure of the root is complete.

### **2.4. Determination of third molar volumes by DentaVol<sup>®</sup>**

We used DentaVol<sup>®</sup> to measure third molar volumes. The program automatically calculated total tooth volume once the third molar was isolated. However, volume of the third molar crown was calculated semi-automatically because the observer must decide where the CEJ is located in the image in order to delete (with the *eraser* tool) the part of the image that corresponds to the tooth root, which appears as a darker shade. Because the CEJ is sinuous, the cervical margin of the crown was defined by the plane that contained the most apical extensions of the enamel. The software calculated mean percentage crown volume in relation to overall tooth volume, and tooth volume data were saved to an Excel spreadsheet for further statistical analysis.

### **2.5. Inter-observer and intra-observer variability**

To test agreement between observers, all MSCT images were evaluated by two trained,

independent observers: a physician specialized in legal medicine (B.S.) and an odontologist with clinical experience and training in forensic odontology (A.B.M.R.). Measurements obtained by only one of the observers (A.B.M.R.) were used for the results reported here. To test intra-observer variability, a random sample of MSCT images from 14 individuals was re-examined 3 weeks after the initial check for agreement.

## **2.6. Statistical analyses**

Statistical analysis was done with SPSS v. 21.0 software (IBM Corporation, Armonk, NY, USA). Descriptive statistics were recorded and expressed as the mean  $\pm$  standard deviation of the mean. Intra- and inter-observer agreement for mineralization stages was determined as the unweighted kappa coefficient [43], and agreement for third molar volumes was determined as the intraclass correlation coefficient (ICC) [44]. The 95% confidence interval (CI) was calculated for each value. The Mann-Whitney  $U$  test was used to analyze age differences between sexes for each stage of mineralization and to search for differences in tooth volumes between sexes in each age group. Differences in mineralization scores and volumes between third molars from the maxillary and mandibular arches were determined with independent sample  $t$ -tests. One-way analysis of variance (ANOVA) was used to identify differences in third molar volumes between age groups. A value of  $p < 0.05$  was considered statistically significant. Linear regression analysis was used to obtain linear regression equations to predict age from percentage crown volume, and to determine the coefficient of determination ( $R^2$ ) for each tooth. Method accuracy was determined by receiver operating characteristic (ROC) analysis, which combines the concepts of sensitivity and specificity into a single measure of accuracy defined as the area under the ROC curve (AUC). Areas between 0.5 and 1 indicated a positive relationship between the rating scale and the correct classification of an individual as younger as or older than 18 years of age. 95% CI for accuracy were calculated with a nonparametric method. The cut-off points were taken as the points nearest the “ideal” point on the ROC curves at which sensitivity was 1 and 1 – specificity was 0 [45,46].

## **3. Results**

### **3.1. Assessment of third molar mineralization stages**

Demirjian’s stages of tooth maturation were determined for all third molars. The kappa



value for intra-observer agreement was 0.87 (95% CI: 0.78-0.97). For inter-observer agreement, the kappa value was high for all third molars, ranging from 0.84 (95% CI: 0.76-0.92) for tooth 38 to 0.90 for teeth 28 and 48 (95% CI: 0.84-0.96).

Age distribution was determined for different mineralization scores according to Demirjian's stages. Table 1 displays the percentage frequency distributions for age group 1 (14.00-15.99 years), age group 2 (16.00-17.99 years) and age group 3 (18.00-23.00 years) according to sex and Demirjian's stages for all four third molars. In the first age group, individuals classified in lower maturity stages (A, B and C) comprised the largest proportion, and this percentage decreased as the degree of mineralization increased. In contrast, in the last age group (individuals 18 years of age or older), the highest percentages of individuals were in the most advanced stages of mineralization (G and H), which means that 100% of individuals classified in stage H were 18 years of age or older. In stage G 100% of women were 18 years of age or older, whereas only 55.6% of men had reached the age of majority according to the results for tooth 18, and only 66.7% according to the results for teeth 28, 38 and 48.

Mean age was determined for each Demirjian's stage and each sex for all four third molars. Mean ages were similar in both sexes except for stages F and G, which showed statistically significant differences between males and females, with third molar maturity occurring earlier in males. In stage F (Figure 3a), differences in mean age according to sex were found for tooth 18 (males vs. females;  $17.56 \pm 1.54$  vs.  $18.89 \pm 1.94$ ;  $p < 0.05$ ), for tooth 38 ( $17.75 \pm 2.17$  vs.  $19.74 \pm 1.59$ ;  $p < 0.05$ ), and for tooth 48 ( $17.56 \pm 1.80$  vs.  $19.60 \pm 2.24$ ;  $p < 0.05$ ). In addition, similar differences were found in stage G (Figure 3b) for tooth 38 ( $18.99 \pm 1.64$  vs.  $20.69 \pm 1.49$ ;  $p < 0.05$ ) and for tooth 48 ( $19.06 \pm 1.57$  vs.  $20.61 \pm 1.61$ ;  $p < 0.05$ ).

Regardless of sex, no statistically significant differences were found in mineralization scores between maxillary and mandibular third molars. Moreover, no significant differences were found in mineralization patterns between upper third molars from either side of the maxilla and between lower third molars from either side of the lower jaw.

We used ROC analysis to determine the accuracy of the examiner's ability to correctly estimate age as younger or older than 18 years on the basis of Demirjian's stages of

mineralization. Table 2 shows the criterion validity for an individual being at least 18 years of age in relation to mineralization scores for all third molars, along with sensitivity, specificity and AUC values for the selected cut-off point to discriminate between stages F, G and H, and lower maturity stages.

### **3.2. Third molar volume**

Total tooth and crown volumes for each third molar were measured with DentaVol<sup>®</sup>. In addition, percentage crown volume in relation to total tooth volume was calculated for each third molar. Inter-observer reproducibility of the measurements with the new software was evaluated by calculating ICC and their 95% CI. The ICC value for intra-observer agreement was 0.99 (95% CI: 0.98-1.00). The ICC for all measurements were higher than 0.98 for all third molars, with 95% CI ranging from 0.97 to 1.

The mean percentage crown volume in relation to overall tooth volume for all four third molars is shown in Table 3 for all age groups and both sexes. Regardless of sex, significant differences were found in mean percentage crown volume among all three age groups for all third molars. In addition, for teeth 38 and 48 significant differences were found in mean percentage crown volume between males and females in age group 2 (Table 3).

However, when the overall sample for each tooth was analyzed, there were no significant differences between sexes in percentage crown volume. In addition, although significant differences were found in mean percentages between maxillary and mandibular third molars ( $60.65 \pm 22.64$  vs.  $65.71 \pm 22.05$ ,  $p < 0.05$ ), no differences were seen between the upper left and lower left third molars, or between the upper right and lower right third molars.

Table 2 shows the criterion validity for an individual being at least 18 years of age based on percentage crown volume in relation to overall tooth volume for all third molars, along with sensitivity, specificity and AUC values for the selected cut-off point, for which sensitivity was higher than 0.80.

Linear regression analyses showed a significant negative correlation between percentage crown volume in relation to overall tooth volume and age for all third

molars. These results indicate that the percentage decreased with increasing age. The strongest correlation was found for tooth 28 ( $R^2 = 0.51$ ,  $p < 0.001$ ), and the following formula was derived to estimate the age of the individual:  $y = 22.90 - 0.08x$  (where  $y$  represents age in years  $x$  represents percentage crown volume) (Figure 4). The standard error of age estimation was  $\pm 1.80$  years. To test the accuracy of this equation for determining the age of majority, we calculated percentage crown volume in 30 upper left third molars from 30 individuals selected randomly from a new sample of the same age range as the initial sample. We then compared the actual ages of this new sample population with the predicted ages. Sensitivity was 0.85 (95% CI: 0.66-1.00) and specificity was 0.71 (95% CI: 0.49-0.93), and no significant differences were found between these values and those obtained when the initial sample was evaluated.

#### **4. Discussion**

Among methods for estimating the chronological age of individuals around the age of 18 years, analysis of third molar mineralization stage has been proposed as one of the most relevant procedures in the absence of other reliable biological markers during late adolescence [5,9]. In most studies tooth mineralization is evaluated in an OPG, and dental age is estimated by comparing dental mineralization status in a person of known or unknown chronological age with dental developmental surveys and standard charts compiled from a large number of persons of known age in a well-defined geographic region (i.e., a reference sample). The eight-stage classification scheme proposed by Demirjian et al. [21] lends itself best to forensic purposes, since stages are defined by changes in shapes and proportions, and the system has been shown to perform best not only in terms of observer agreement but also in terms of the correlation between estimated and true age [17–19,24–26,28–30].

However, OPGs are two-dimensional panoramic radiographs of both dental arches where bone structures or teeth can overlap, and third molar roots may not be visible in the most suitable position for analysis. In these circumstances it is enormously difficult to discern the threshold between one maturational stage and another, and the use of 3D dental imaging techniques such as CT and MRI is currently widespread for legal age estimation [31–38]. Previous studies have used third molar mineralization based on Demirjian's stages with CT to establish dental age [39–42], but to our knowledge this is the first study to provide comparable data on third molar maturation stages (qualitative method) and volume measurements (quantitative method) in the same population

sample with DentaVol<sup>®</sup>, an accurate 3D image visualization software.

The reliability of both qualitative and quantitative procedures was verified by intra- and inter-observer agreement studies. Agreement for the evaluation of mineralization stages by different experts was “perfect” or “substantial” according to the six-category system proposed by Landis and Koch [47], with kappa values for all third molars ranging from 0.84 to 0.90. In assessments of the reproducibility of volume measurements obtained with the new DentaVol<sup>®</sup> software, ICC values were higher than 0.98 for all third molars – a value that can be considered “perfect” [47]. Overall, our inter-observer values for both procedures were remarkably high and similar to those obtained by others [11,17,18,36]. Regarding studies of third molar maturation to identify possible differences between right and left third molars, our results are consistent with previous studies [18–20,38,40] in that there were no significant differences between molars from either side of the maxilla or mandible. In addition, a comparison of mineralization stages disclosed no differences with time in the mineralization process of the upper and lower third molars, in agreement with previous studies [28]. However, we noted some remarkable differences between upper and lower third molars in our molar volumetry results. When the overall sample was analyzed, percentage crown volume for lower third molars was higher than the percentage volumes estimated for upper third molars, although there were no differences between upper and lower third molars when the results were analyzed separately for each side of the dental arches. Therefore, a possible reason for the higher volumes in lower molars is the anatomical singularity of these teeth, rather than differences in trends for third molar maturation.

In agreement with most previous studies of third molar development in different sexes, males in our sample showed earlier dental development than females [15,18,24,28,38]. Mean ages at stages F and G showed evident sexual dimorphism, with third molar maturity occurring earlier in males than females. Moreover, the faster rate of tooth formation in males was also evident when the data were expressed as mean percentage crown volume in age group 2 (individuals 16 to 18 years old) (Table 3).

The main aim of the present study was to determine the accuracy of legal age determination by contrasting the stages wisdom tooth mineralization with volumetric values for the same population sample with DentaVol<sup>®</sup>. We found a correlation between third molar development and chronological age (Figure 4), corroborating the results of

previous studies [18,19,28,39]. Moreover, we report the first estimates of average tooth volumes for each Demirjian stage and for all third molars (see results for tooth 48 in Figure 2).

We used ROC analysis to determine the accuracy of the examiner's ability to correctly estimate age as younger or older than 18 years on the basis of the two criteria compared in this study: Demirjian's stage of wisdom tooth mineralization and percentage crown volume in relation to overall tooth volume. Fairly high AUC values (from 0.83 to 0.87) were found for the two procedures in all third molars according to Swets's scoring system (Table 2). A diagnostic test is considered "highly accurate" when the AUC is 0.9, "useful for some purposes" at 0.7–0.9, and "poor" at 0.5–0.7 [48]. Thus, determination of the stage of third molar maturation with both procedures can be considered a good indicator of age 18 years or older in all third molars.

Sensitivity, specificity and 95% CI for each cut-off point for both procedures in all third molars are shown in Table 2. Low sensitivity values mean that the method should be used with caution as a screening test. The highest sensitivity in all third molars was found for the cut-off point which discriminated between stage E of dental maturation according to Demirjian's system (the crown is complete, inter-radicular bifurcation has started, and the root is shorter than the crown) and stages F, G and H, which indicate continuing root formation. However, forensic tests used to estimate age should minimize false positives to avoid mistakenly classifying minors as over 18 years of age. The main aim of forensic tests should be to correctly classify individuals who are younger than 18 years. In this study, high specificity values for molar maturation (around 0.8; see Table 2) were also found by estimating percentage crown volume with DentaVol<sup>®</sup>. In addition, the linear regression equation for tooth 28 was able to correctly classify 76.7% of the individuals in a new sample as younger or older than 18 years of age, on the basis of percentage crown volume.

What do our data suggest with regard to differences between procedures to estimate tooth mineralization? First, these findings have important implications for forensic practice concerning tooth mineralization, because MSCT data led to more accurate determinations of tooth maturation stage than OPGs. The reason for this may be that in OPGs, the molar roots are at risk of appearing superimposed. This possibility is additionally supported by the fact that teeth which could not be assessed were

predominantly located in the upper jaw, where most molars have three roots. In addition, third molar volumes were successfully analyzed by calculating total tooth molar and crown volumes with the straightforward imaging tool provided with DentaVol<sup>®</sup>. This custom-made software for image analysis obviates the need for complex algorithms, familiarity with imaging fundamentals and even dental anatomical knowledge, which are usually needed for medical imaging procedures. Therefore, dental age estimation from the study of qualitative (maturational stage) and quantitative parameters (percentage crown volume) of dental development with DentaVol<sup>®</sup> can be considered an accurate indicator of age of majority.

In conclusion, virtual computed tomography imaging is an alternative to orthopantomography for the assessment of third molar mineralization, and this approach can also incorporate volumetric data when DentaVol<sup>®</sup>, a new tool for forensic imaging, is used. The present study thus reports a potentially useful alternative, complementary method for dental age estimation.

#### **Conflict of interest**

The authors declare that they have no conflict of interest.

#### **Acknowledgments**

Appreciation is expressed to the Diagnostic and Image Center of University Hospital Dr. Eleuterio González in Monterrey, Mexico, and Prof. Dr. Eloy Girela-López from the University of Cordoba, Spain, for help with obtaining MSCT images. We thank Dr Francisco J. Rodríguez-Prados, Prof. Dr. Juan Carlos Torres-Cantero and Dr. Francisco Soler-Martínez for their technical expertise and scientific advice in the design and update of the DentaVol<sup>®</sup> software. We thank K. Shashok for improving the use of English in the manuscript. This research was supported by Research Excellence Project P09-SEJ-4738, 2010 from the Andalusian Regional Government, Spain. The authors also acknowledge funding from CEIFA (Centro para la Excelencia en Investigación Forense en Andalucía). Ana Belén Márquez-Ruiz was the recipient of an FPU (Formación del Profesorado Universitario) grant FPU13/03543 from the Spanish Ministry of Education, Culture and Sports.

## References

- [1] A. Schmeling, W. Reisinger, G. Geserick, A. Olze, Age estimation of unaccompanied minors. Part I. General considerations, *Forensic Sci. Int.* 159 Suppl (2006) S61-S64. doi:10.1016/j.forsciint.2006.02.017.
- [2] A. Schmeling, A. Olze, W. Reisinger, F.W. Rosing, G. Geserick, Forensic age diagnostics of living individuals in criminal proceedings, *Homo.* 54 (2003) 162–169.
- [3] P. Beh, J. Payne-James, Clinical and Legal Requirements for Age Determination in the Living, in: *Age Estim. Living*, John Wiley & Sons, Ltd, 2010: pp. 30–42. doi:10.1002/9780470669785.ch3.
- [4] H.M. Liversidge, J. Buckberry, N. Marquez-Grant, Age estimation, *Ann. Hum. Biol.* 42 (2015) 299–301. doi:10.3109/03014460.2015.1089627.
- [5] T.J. Cole, The evidential value of developmental age imaging for assessing age of majority, *Ann. Hum. Biol.* 42 (2015) 379–388. doi:10.3109/03014460.2015.1031826.
- [6] R.B. Bassed, C. Briggs, O.H. Drummer, Age estimation using CT imaging of the third molar tooth, the medial clavicular epiphysis, and the spheno-occipital synchondrosis: a multifactorial approach, *Forensic Sci. Int.* 212 (2011) 273.e1-273.e5. doi:10.1016/j.forsciint.2011.06.007.
- [7] D. Wittschieber, C. Ottow, V. Vieth, M. Kuppers, R. Schulz, J. Hassu, T. Bajanowski, K. Puschel, F. Ramsthaler, H. Pfeiffer, S. Schmidt, A. Schmeling, Projection radiography of the clavicle: still recommendable for forensic age diagnostics in living individuals? *Int. J. Legal Med.* 129 (2015) 187–193. doi:10.1007/s00414-014-1067-0.
- [8] R.B. Bassed, O.H. Drummer, C. Briggs, A. Valenzuela, Age estimation and the medial clavicular epiphysis: analysis of the age of majority in an Australian population using computed tomography, *Forensic Sci. Med. Pathol.* 7 (2011) 148–154. doi:10.1007/s12024-010-9200-y.
- [9] D. Wittschieber, C. Ottow, R. Schulz, K. Puschel, T. Bajanowski, F. Ramsthaler, H. Pfeiffer, V. Vieth, S. Schmidt, A. Schmeling, Forensic age diagnostics using projection radiography of the clavicle: a prospective multi-center validation study, *Int. J. Legal Med.* 130 (2016) 213–219. doi:10.1007/s00414-015-1285-0.
- [10] A. Schmeling, C. Grundmann, A. Fuhrmann, H.J. Kaatsch, B. Knell, F. Ramsthaler, W. Reisinger, T. Riepert, S. Ritz-Timme, F.W. Rosing, K. Rotzcher, G. Geserick, Criteria for age estimation in living individuals, *Int. J. Legal Med.* 122 (2008) 457–460. doi:10.1007/s00414-008-0254-2.

- [11] P.M. Garamendi, M.I. Landa, J. Ballesteros, M.A. Solano, Reliability of the methods applied to assess age minority in living subjects around 18 years old. A survey on a Moroccan origin population, *Forensic Sci. Int.* 154 (2005) 3–12. doi:S0379-0738(04)00630-9 [pii].
- [12] E. Scheurer, F. Quehenberger, M.T. Mund, H. Merkens, K. Yen, Validation of reference data on wisdom tooth mineralization and eruption for forensic age estimation in living persons, *Int. J. Legal Med.* 125 (2011) 707–715. doi:10.1007/s00414-011-0587-0.
- [13] A. Demirjian, P.H. Buschang, R. Tanguay, D.K. Patterson, Interrelationships among measures of somatic, skeletal, dental, and sexual maturity, *Am. J. Orthod.* 88 (1985) 433–438.
- [14] G.J. Roberts, S. Parekh, A. Petrie, V.S. Lucas, Dental age assessment (DAA): a simple method for children and emerging adults, *Br. Dent. J.* 204 (2008) E7; discussion 192-3. doi:10.1038/bdj.2008.21.
- [15] A. Olze, W. Reisinger, G. Geserick, A. Schmeling, Age estimation of unaccompanied minors. Part II. Dental aspects, *Forensic Sci. Int.* 159 Suppl (2006) S65-7. doi:S0379-0738(06)00075-2 [pii].
- [16] G. Willems, A review of the most commonly used dental age estimation techniques, *J. Forensic Odontostomatol.* 19 (2001) 9–17.
- [17] A. Olze, D. Bilang, S. Schmidt, K.D. Wernecke, G. Geserick, A. Schmeling, Validation of common classification systems for assessing the mineralization of third molars, *Int. J. Legal Med.* 119 (2005) 22–26. doi:10.1007/s00414-004-0489-5.
- [18] S. Martin-de las Heras, P. Garcia-Forteza, A. Ortega, S. Zdocovich, A. Valenzuela, Third molar development according to chronological age in populations from Spanish and Magrebian origin, *Forensic Sci. Int.* 174 (2008) 47–53. doi:S0379-0738(07)00149-1 [pii].
- [19] J.L. Prieto, E. Barberia, R. Ortega, C. Magana, Evaluation of chronological age based on third molar development in the Spanish population, *Int. J. Legal Med.* 119 (2005) 349–354. doi:10.1007/s00414-005-0530-3.
- [20] H.H. Mincer, E.F. Harris, H.E. Berryman, The A.B.F.O. study of third molar development and its use as an estimator of chronological age, *J. Forensic Sci.* 38 (1993) 379–390.
- [21] A. Demirjian, H. Goldstein, J.M. Tanner, A new system of dental age assessment, *Hum. Biol.* 45 (1973) 211–227.
- [22] G. Willems, A. Van Olmen, B. Spiessens, C. Carels, Dental age estimation in Belgian



- children: Demirjian's technique revisited, *J. Forensic Sci.* 46 (2001) 893–895.
- [23] R. Cameriere, L. Ferrante, D. De Angelis, F. Scarpino, F. Galli, The comparison between measurement of open apices of third molars and Demirjian stages to test chronological age of over 18 year olds in living subjects, *Int. J. Legal Med.* 122 (2008) 493–497. doi:10.1007/s00414-008-0279-6.
- [24] A.C. Solari, K. Abramovitch, The accuracy and precision of third molar development as an indicator of chronological age in Hispanics, *J. Forensic Sci.* 47 (2002) 531–535.
- [25] A. De Salvia, C. Calzetta, M. Orrico, D. De Leo, Third mandibular molar radiological development as an indicator of chronological age in a European population, *Forensic Sci. Int.* 146 Suppl (2004) S9–S12. doi:S0379-0738(04)00502-X [pii].
- [26] N. Chaillet, M. Nystrom, A. Demirjian, Comparison of dental maturity in children of different ethnic origins: international maturity curves for clinicians, *J. Forensic Sci.* 50 (2005) 1164–1174.
- [27] K. Gunst, K. Mesotten, A. Carbonez, G. Willems, Third molar root development in relation to chronological age: a large sample sized retrospective study, *Forensic Sci. Int.* 136 (2003) 52–57. doi:S0379073803002639 [pii].
- [28] C.B. Soares, J.N. Figueiroa, R.M. Dantas, L.M. Kurita, A. Pontual Ados, F.M. Ramos-Perez, D.E. Perez, M.L. Pontual, Evaluation of third molar development in the estimation of chronological age, *Forensic Sci. Int.* 254 (2015) 13–17. doi:10.1016/j.forsciint.2015.06.022.
- [29] P. Streckbein, I. Reichert, M.A. Verhoff, R.H. Bodeker, C. Kahling, J.F. Wilbrand, H. Schaaf, H.P. Howaldt, A. May, Estimation of legal age using calcification stages of third molars in living individuals, *Sci. Justice.* 54 (2014) 447–450. doi:10.1016/j.scijus.2014.08.005.
- [30] G. Feijoo, E. Barberia, J. De Nova, J.L. Prieto, Dental age estimation in Spanish children, *Forensic Sci. Int.* 223 (2012) 371.e1-371.e5. doi:10.1016/j.forsciint.2012.08.021.
- [31] K. Zhang, X.G. Chen, H. Zhao, X.A. Dong, Z.H. Deng, Forensic Age Estimation Using Thin-Slice Multidetector CT of the Clavicular Epiphyses Among Adolescent Western Chinese, *J. Forensic Sci.* 60 (2015) 675–678. doi:10.1111/1556-4029.12739.
- [32] K.L. Boyd, C. Villa, N. Lynnerup, The use of CT scans in estimating age at death by examining the extent of ectocranial suture closure, *J. Forensic Sci.* 60 (2015) 363–369. doi:10.1111/1556-4029.12683.
- [33] N. Pattamapaspong, C. Madla, K. Mekjaidee, S. Namwongprom, Age estimation of a Thai population based on maturation of the medial clavicular epiphysis using computed

tomography, *Forensic Sci. Int.* 246 (2015) 123.e1-123.e5.

doi:10.1016/j.forsciint.2014.10.044.

- [34] O. Ekizoglu, E. Hocaoglu, E. Inci, I. Sayin, D. Solmaz, M.G. Bilgili, I.O. Can, Forensic age estimation by the Schmeling method: computed tomography analysis of the medial clavicular epiphysis, *Int. J. Legal Med.* 129 (2015) 203–210. doi:10.1007/s00414-014-1121-y.
- [35] M. Lopez-Alcaraz, P.M. Gonzalez, I.A. Aguilera, M.B. Lopez, Image analysis of pubic bone for age estimation in a computed tomography sample, *Int. J. Legal Med.* 129 (2015) 335–346. doi:10.1007/s00414-014-1034-9.
- [36] P. Baumann, T. Widek, H. Merkens, J. Boldt, A. Petrovic, M. Urschler, B. Kirnbauer, N. Jakse, E. Scheurer, Dental age estimation of living persons: Comparison of MRI with OPG, *Forensic Sci. Int.* 253 (2015) 76–80. doi:10.1016/j.forsciint.2015.06.001.
- [37] E. Hillewig, J. Degroote, T. Van der Paelt, A. Visscher, P. Vandemaele, B. Lutin, L. D’Hooghe, V. Vandriessche, M. Piette, K. Verstraete, Magnetic resonance imaging of the sternal extremity of the clavicle in forensic age estimation: towards more sound age estimates, *Int. J. Legal Med.* 127 (2013) 677–689. doi:10.1007/s00414-012-0798-z.
- [38] Y. Guo, A. Olze, C. Ottow, S. Schmidt, R. Schulz, W. Heindel, H. Pfeiffer, V. Vieth, A. Schmeling, Dental age estimation in living individuals using 3.0 T MRI of lower third molars, *Int. J. Legal Med.* 129 (2015) 1265–1270. doi:10.1007/s00414-015-1238-7.
- [39] R.B. Bassed, C. Briggs, O.H. Drummer, Age estimation and the developing third molar tooth: an analysis of an Australian population using computed tomography, *J. Forensic Sci.* 56 (2011) 1185–1191. doi:10.1111/j.1556-4029.2011.01769.x.
- [40] M.C. Trevino-Tijerina, A. Valenzuela-Garach, R.A. Elizondo-Pereo, R.M. Cerda-Flores, J. Vargas-Villarreal, F. González-Salazar, D.A. Valenzuela-Garach, R.A. Elizondo-Pereo, R.M. Cerda-Flores, J. Vargas-Villarreal, F. Gonzalez-Salazar, Age estimation of teenagers from Monterrey (Mexico) by the evaluation of dental mineralization after multi-slice helical computed tomography, *Aust. J. Forensic Sci.* 48 (2016) 138–149. doi:10.1080/00450618.2015.1034777.
- [41] J.P. Graham, C.J. O’Donnell, P.J. Craig, G.L. Walker, A.J. Hill, G.N. Cirillo, R.M. Clark, S.R. Gledhill, M.E. Schneider-Kolsky, The application of computerized tomography (CT) to the dental ageing of children and adolescents, *Forensic Sci. Int.* 195 (2010) 58–62. doi:10.1016/j.forsciint.2009.11.011.
- [42] F. Yang, R. Jacobs, G. Willems, Dental age estimation through volume matching of teeth imaged by cone-beam CT, *Forensic Sci. Int.* 159 Suppl (2006) S78-S83.

doi:S0379- 0738(06)00078-8 [pii].

- [43] J. Fleiss, B. Levin, M. Cho Paik, *Statistical Methods for Rates and Proportions*, John Wiley & Sons, Inc., Hoboken, NJ, USA, 2003. doi:10.1198/tech.2004.s812.
- [44] J.L. Fleiss, *The Design and Analysis of Clinical Experiments*, John Wiley & Sons, Inc., Hoboken, NJ, USA, 1999. doi:10.1002/9781118032923.
- [45] J.A. Hanley, B.J. McNeil, The meaning and use of the area under a receiver operating characteristic (ROC) curve, *Radiology*. 143 (1982) 29–36. doi:10.1148/radiology.143.1.7063747.
- [46] M.H. Zweig, G. Campbell, Receiver-operating characteristic (ROC) plots: a fundamental evaluation tool in clinical medicine, *Clin. Chem*. 39 (1993) 561–577.
- [47] J.R. Landis, G.G. Koch, The measurement of observer agreement for categorical data, *Biometrics*. 33 (1977) 159–174.
- [48] J.A. Swets, Measuring the accuracy of diagnostic systems., *Science*. 240 (1988) 1285–1293. doi:10.1126/science.3287615.

### Figure captions

**Fig. 1** DentaVol<sup>®</sup> interfaces (1: toolbar, 2: display area, 3: grayscale filter, 4: case study data area) and sequence of image processing (a: 3D image visualization, b: selection of the area of interest, c: isolation of the third molar, d: volume measurements).

**Fig. 2** Comparison between the eight-stage classification scheme of Demirjian and third molar 3D images obtained by DentaVol<sup>®</sup>, with mean total volumes ( $\pm$  SD) expressed in mm<sup>3</sup> for each stage in tooth 48.

**Fig. 3** Box plot of age vs. Demirjian's stage F (a) and G (b) in all four third molars and both sexes. The horizontal line indicates the median, the box represents the interquartile range, and the vertical lines represent the minimum and maximum values. Statistically significant differences between sexes are indicated by asterisks.

**Fig. 4** Correlation between percentage crown volume in relation to overall tooth volume and age for tooth 28. The solid straight line represents the linear regression, and the dotted straight lines show the 95% confidence intervals for the individual predicted values.

**Table 1** Percentage frequency distributions for all age groups<sup>a</sup> according to sex and Demirjian's stages for all four third molars.

Stage, sex	Tooth 18				Tooth 28				Tooth 38				Tooth 48				
	Age group 1	Age group 2	Age group 3	<i>n</i>	Age group 1	Age group 2	Age group 3	<i>n</i>	Age group 1	Age group 2	Age group 3	<i>n</i>	Age group 1	Age group 2	Age group 3	<i>n</i>	
A, males				100				1	100				1				
B, males				100				2	100				1	100			
B, females	100			1	100			1						100			
C, males	80	20		10	71.4	28.6		7	100				6	60	30	10	
C, females	87.5	12.5		8	83.3	16.7		6	40	60			5	57.1	42.9		
D, males	33.3	66.7		3	60	40		5	37.5	25	37.5		8	37.5	25	37.5	
D, females	50	28.6	21.4	14	61.5	23.1	15.4	13	60	25	15	20	63.2	26.3	10.5	19	
E, males	37.5	37.5	25	8	28.6	42.8	28.6	7	40	40	20	10	40	60		5	
E, females	20		80	5	12.5	25	62.5	8	66.7	33.3		3	50		50	2	
F, males	18.2	45.4	36.4	22	20.8	41.7	37.5	24	17.6	47.1	35.3	17	20	40	40	15	
F, females	9.1	27.3	63.6	11	10	20	70	10		11.1	88.9	9	10	10	80	10	
G, males	11.1	33.3	55.6	9		33.3	66.7	9		33.3	66.7	12		33.3	66.7	15	
G, females			100	11				100	9			100	13				
H, males			100	9				100	9			100	8			100	
H, females			100	4				100	4			100	1			100	

<sup>a</sup> Age group 1: 14.00-15.99 years; Age group 2: 16.00-17.99 years; Age group 3: 18.00-23.00 years.  
*n*: number of cases.

**Table 2** Sensitivity, specificity and AUC<sup>a</sup> values for the selected cut-off point for the two procedures and all four third molars.

Tooth	Demirjian's stages <sup>b</sup>			Percentage crown volume <sup>c</sup>		
	Sensitivity <sup>d</sup>	Specificity <sup>d</sup>	AUC <sup>a</sup>	Sensitivity <sup>d</sup>	Specificity <sup>d</sup>	AUC <sup>a</sup>
18	0.83 (0.73-0.93)	0.64 (0.53-0.76)	0.851	0.81 (0.69-0.89)	0.72 (0.58-0.82)	0.828
28	0.83 (0.73-0.93)	0.66 (0.54-0.78)	0.859	0.81 (0.69-0.89)	0.70 (0.57-0.81)	0.851
38	0.85 (0.75-0.94)	0.74 (0.63-0.85)	0.859	0.79 (0.67-0.87)	0.75 (0.62-0.85)	0.842
48	0.87 (0.78-0.96)	0.74 (0.63-0.85)	0.868	0.80 (0.69-0.88)	0.78 (0.65-0.87)	0.852

<sup>a</sup> AUC: area under the ROC curve.

<sup>b</sup> Criterion validity was defined as predictive validity for chronological age  $\geq$  18 years. The cut-off point discriminated between Demirjian's stages F, G and H, and lower maturity stages.

<sup>c</sup> Criterion validity was defined as predictive validity for chronological age  $\geq$  18 years. The cut-off point was sensitivity  $>0.80$ .

<sup>d</sup> Results are expressed as means (minimum values-maximum values) at 95% confidence intervals.

**Table 3** Mean percentage crown volume in relation to overall tooth volume according to sex and age group<sup>a</sup> for all four third molars.

Tooth		Total sample		Age group 1		Age group 2		Age group 3	
		Mean $\pm$ SD	<i>n</i>	Mean $\pm$ SD	<i>n</i>	Mean $\pm$ SD	<i>n</i>	Mean $\pm$ SD	<i>n</i>
18	Males	57.32 $\pm$ 22.38	61	77.78 $\pm$ 24.66	17	55.82 $\pm$ 19.22	20	44.07 $\pm$ 9.12	24
	Females	64.20 $\pm$ 23.16	54	87.94 $\pm$ 15.61	17	72.15 $\pm$ 21.34	8	48.09 $\pm$ 11.54	29
	Total	60.55 $\pm$ 22.91	115	82.86 $\pm$ 20.97*	34	60.49 $\pm$ 20.84*	28	46.27 $\pm$ 10.61*	53
28	Males	58.36 $\pm$ 22.29	64	78.71 $\pm$ 22.68	18	57.80 $\pm$ 20.67	20	44.69 $\pm$ 9.23	26
	Females	63.77 $\pm$ 22.54	51	87.30 $\pm$ 14.16	16	71.19 $\pm$ 21.32	8	47.62 $\pm$ 10.52	27
	Total	60.76 $\pm$ 22.47	115	82.75 $\pm$ 19.37*	34	61.63 $\pm$ 21.36*	28	46.18 $\pm$ 9.92*	53
38	Males	61.28 $\pm$ 20.84	63	81.33 $\pm$ 18.84	18	57.03 $\pm$ 12.54**	18	50.75 $\pm$ 17.17	27
	Females	69.86 $\pm$ 22.25	51	90.24 $\pm$ 11.35	16	81.88 $\pm$ 18.88**	10	52.00 $\pm$ 12.15	25
	Total	65.12 $\pm$ 21.81	114	85.52 $\pm$ 16.18*	34	65.91 $\pm$ 19.10*	28	51.35 $\pm$ 14.84*	52
48	Males	62.58 $\pm$ 21.98	61	82.34 $\pm$ 20.31	15	61.17 $\pm$ 19.13**	19	52.60 $\pm$ 17.58	27
	Females	69.93 $\pm$ 22.43	55	90.33 $\pm$ 11.07	18	82.09 $\pm$ 19.79**	10	51.83 $\pm$ 12.01	27
	Total	66.06 $\pm$ 22.40	116	86.70 $\pm$ 16.18*	33	68.38 $\pm$ 21.53*	29	52.21 $\pm$ 14.92*	54

SD: standard deviation; *n*: number of cases.

<sup>a</sup> Age groups are as explained in the footnote to Table 1.

\* Statistically significant differences between age groups for teeth 18, 28, 38 and 48: Age group 1 vs. Age group 2 ( $p < 0.001$ ), Age group 1 vs. Age group 3 ( $p < 0.001$ ), and Age group 2 vs. Age group 3 ( $p < 0.001$ ).

\*\* Statistically significant differences between sexes within Age group 2: tooth 38  $p < 0.05$ , tooth 48  $p < 0.05$ .

Figure 1

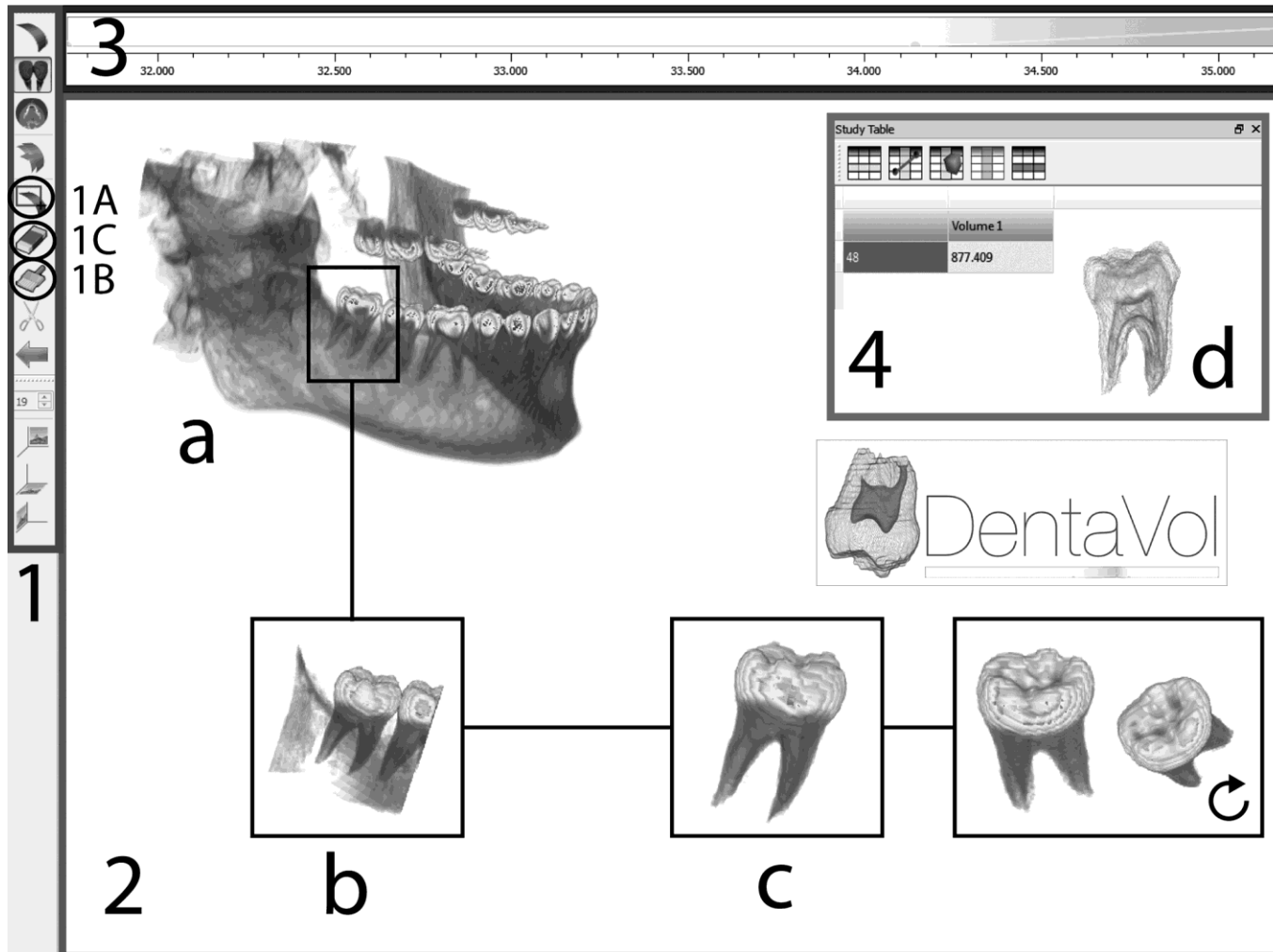


Figure 2

















Demirjian's stage	A	B	C	D	E	F	G	H
Demirjian's scheme								
DentaVol <sup>®</sup> image								
Mean total volume	N.A.	123.9±8.5	212.1±50.6	318.8±110.8	472.6±52.9	572.6±141.4	617.4±79.5	669.9±148.9



Figure 3

