

of a mass in the neck is the most common symptom. The mechanism that causes diarrhoea is fundamentally fluid and electrolyte secretion, induced by various peptides (calcitonin, serotonin, VIP),^{2,4} although there may also be an increase in intestinal motility.

Initial screening tests for these tumours include an ultrasound of the neck.⁵ The most sensitive diagnostic test is the cytologic smear using a fine-needle aspiration biopsy with positive staining for calcitonin, chromogranin A and carcinoembryonic antigen.⁶ Plasma calcitonin and carcinoembryonic antigen levels are useful for diagnosing and monitoring this type of tumour.⁷ Calcitonin, although not a specific marker, also correlates with the extent of the disease.⁸

In 75% of cases, MTC is sporadic, while in 25% of cases it is hereditary. It is generally associated with multiple endocrine neoplasia and hereditary MTC due to RET proto-oncogene mutation. This mutation should be studied in all patients diagnosed with this type of tumour, and appropriate genetic counselling should be provided.^{9,10}

This is an interesting case because chronic diarrhoea was the patient's only symptom, but a diagnosis of metastatic MTC was reached. A detailed medical history and a thorough physical examination are essential to determine which patients require complementary examinations and tests.

References

1. Thomas PD, Forbes A, Green J, Howdle P, Long R, Playford R, et al. Guidelines for the investigation of chronic diarrhoea, 2nd edition. *Gut*. 2003;52:1–15.
2. Jensen RT. Overview of chronic diarrhea caused by functional neuroendocrine neoplasms. *Semin Gastrointest Dis*. 1999;10:156–72.
3. Wells SA Jr, Asa SL, Dralle H, Elisei R, Evans DB, Gagel RF, et al. Revised American Thyroid Association Guidelines for the management of medullary thyroid carcinoma. *Thyroid*. 2015;25:567–610.
4. Hanna FWF, Ardill JES, Johnston CF, Cunningham RT, Curry WJ, Russell CFJ, et al. Regulatory peptides and other neuroendocrine markers in medullary carcinoma of the thyroid. *J Endocrinol*. 1997;152:275–81.
5. Kouvaraki MA, Shapiro SE, Fornage BD, Edeiken-Monro BS, Sherman SI, Vassilopoulou-Sellin R, et al. Role of preoperative ultrasonography in the surgical management of patients with thyroid cancer. *Surgery*. 2003;134:946–54.
6. Trimboli P, Treglia G, Guidobaldi L, Romanelli F, Nigri G, Valabrega S, et al. Detection rate of FNA cytology in medullary thyroid carcinoma: a meta-analysis. *Clin Endocrinol (Oxf)*. 2015;82:280–5.
7. Costante G, Durante C, Francis Z, Schlumberger M, Filetti S. Determination of calcitonin levels in C-cell disease: clinical interest and potential pitfalls. *Nat Clin Pract Endocrinol Metab*. 2009;5:35–44.
8. Machens A, Dralle H. Biomarker-based risk stratification for previously untreated medullary thyroid cancer. *J Clin Endocrinol Metab*. 2010;95:2655–63.
9. Lips CJ, Hoppener JW, van Nesselrooij BP, van der Lijst RB. Counselling in multiple endocrine neoplasia syndromes: from individual experience to general guidelines. *J Intern Med*. 2005;257:69–77.
10. Mulligan LM, Kwok JBJ, Healey CS, Elsdon MJ, Eng C, Gardner E, et al. Germ-line mutations of the RET protooncogene in multiple endocrine neoplasia type-2A. *Nature*. 1993;363:458–60.

Ander Ernaga Lorea^{a,*}, Iranzu Migueliz Bermejo^b, Nerea Eguilaz Esparza^a, María Cecilia Hernández Morhain^a, Javier Pineda Arribas^a

^a Complejo Hospitalario de Navarra, Pamplona, Navarra, Spain

^b Centro de Salud de San Jorge, Pamplona, Navarra, Spain

* Corresponding author.

E-mail address: andernaga@hotmail.es

(A. Ernaga Lorea).

2444-3824/

© 2017 Elsevier España, S.L.U. All rights reserved.

Co-infection by lymphogranuloma venereum and *Haemophilus parainfluenzae* during an episode of proctitis[☆]

Co-infección por linfogranuloma venéreo y *Haemophilus parainfluenzae* durante un episodio de proctitis

Anorectal disease is a common finding in men who have sex with men (MSM). The most common causes tend to be



HIV-related or non-HIV-related infections. These causes include lesions caused by herpes simplex virus, *Treponema pallidum*, *Neisseria gonorrhoeae* (*N. gonorrhoeae*), *Chlamydia trachomatis* (*C. trachomatis*), *Shigella* spp. and protozoan infections. Invasive *C. trachomatis* genotypes (L1-L3) cause lymphogranuloma venereum (LGV), which used to be considered a rare finding in developed countries.¹ However, since 2003, numerous cases have been reported in Europe and the United States, primarily among MSM, with the main infections manifested including proctitis² associated with circulation of the L2b variant. Diagnosis has improved thanks to the use of molecular techniques on direct samples, and genotyping of LGV-producing genovars. Treatment for LGV is not completely standardised since doxycycline or azithromycin can be used with variable doses and duration of therapy. This paper looks at an uncommon cause of proctitis due to co-infection by *C. trachomatis* and *Haemophilus parainfluenzae* (*H. parainfluenzae*).

The patient is a 34-year-old male who has unprotected sex with other men. The patient has a history of acute hepatitis B from 2013 and has now achieved seroconversion

[☆] Please cite this article as: Caballero-Mateos AM, López de Hierro-Ruiz M, Rodríguez-Domínguez M, Galán-Montemayor JC, Gutiérrez-Fernández J. Co-infección por linfogranuloma venéreo y *Haemophilus parainfluenzae* durante un episodio de proctitis. *Gastroenterol Hepatol*. 2018;41:107–109.

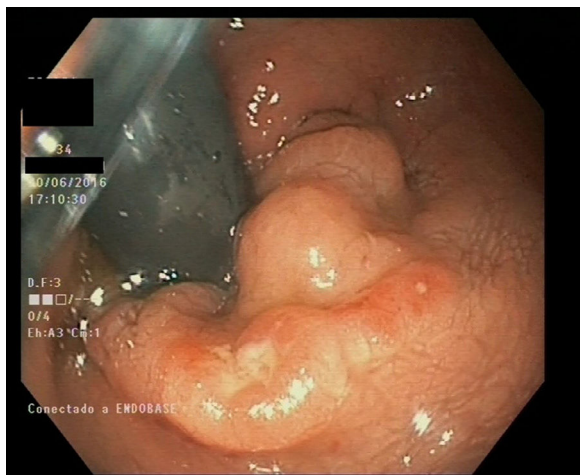


Figure 1 Endoscopic image of lesion in the rectum.

(HBsAg negative, HBsAb positive) with secondary syphilis. He is not infected with HIV. He is a regular user of cocaine, inhaled nitrates, speed and lysergic acid derivatives. He has a cat, a boa constrictor and 12 rats, which do not get veterinary health check-ups. The patient attended the emergency department after suffering from severe proctalgia for 2 days, accompanied by constipation, self-limited episode of rectal bleeding and a fever of 38°C with no apparent source. One week ago, he manually extracted stool from his rectum (self-disimpaction). A non-specific rectal ulcer with raised edges was observed on the colonoscopy with central depression and fibrinous base (Fig. 1). Biopsies were taken for examination. The patient was polymerase chain reaction (PCR) positive for LGV-related genotypes in laboratory tests. Subsequent allele-specific PCR based on 3 aa (9 pb) deletion between L2 positions 591–592 and *pmpH* gene sequencing determined that the strain belongs to the invasive L2 genotype³ as it showed the specific P159L mutation. Growth of *H. parainfluenzae* was observed in culture media. An E-test was performed to test antimicrobial susceptibility; it was susceptible to trimethoprim/sulfamethoxazole (MIC: 0.19 mg/l), ampicillin (MIC: 0.38 mg/l), amoxicillin-clavulanic acid (MIC: 0.38 mg/l), cefixime (MIC: <0.016 mg/l), levofloxacin (MIC: 0.064 mg/l), tetracycline (MIC: 0.047 mg/l) and azithromycin (MIC: 3 mg/l). Finally, doxycycline 100 mg/12 h was prescribed for 21 days. The patient has been asymptomatic since then.

No previous case of rectal ulcer with the presence of *H. parainfluenzae*, either alone or with other microorganisms, has been described to date. Finding both *H. parainfluenzae* and LGV genotype L2, which is less prevalent in our environment than genotype L2b, primarily associated with the re-emergence of LGV in Europe, makes this a noteworthy, previously unpublished case, which coincides with that indicated for LGV in European papers,⁴ but is different from that detected in nearby geographical areas.⁵ The patient's symptoms may of course be due almost exclusively to LGV infection and not to *Haemophilus*, although this can behave as an opportunistic pathogen and take advantage of the epithelial lesion caused by LGV.

We are currently witnessing epidemiological changes in the aetiology of sexually transmitted infections and/or

infections in unusual sites, which will require a more complete diagnostic approach, with the requirement for more testing and adaptation of available diagnostic procedures to clinical needs.^{6–8} In cases of proctitis, especially in MSM, use of anoscopy or rectosigmoidoscopy with sampling should be assessed, regardless of whether there is a lesion or not. However, there are currently no parallel cost-effectiveness studies showing whether such use is profitable in our health system. It must be remembered that there are no pathognomonic lesions for this type of disease, and lesions can sometimes be confused with those that are secondary to inflammatory bowel disease. Microbiological culture of fastidious bacteria, PCR assay for the detection of herpes simplex virus, *N. gonorrhoeae* and *C. trachomatis*, and their serotyping, when possible, are considered essential tests.

C. trachomatis infection, and specifically the onset of LGV in developed countries, has been shown to be linked to HIV infection (in up to 70% of cases) in MSM with multiple partners, but no link has been shown with the level of immunosuppression. In our case, the patient was not infected with HIV. Other independent risk factors include a history of sexually transmitted diseases, unprotected anal intercourse, travel abroad and encounters with sexual partners found via the internet.^{9,10}

References

- Scieux C, Barnes R, Bianchi A, Casin I, Morel P, Perol Y. Lymphogranuloma venereum: 27 cases in Paris. *J. Infect. Dis.* 1989;160:662–8.
- Van der Bij AK, Spaargaren J, Morré SA, Fennema HS, Mindel A, Coutinho RA, et al. Diagnostic and clinical implications of anorectal lymphogranuloma venereum in men who have sex with men: a retrospective case-control study. *Clin Infect Dis.* 2006;42:186–94.
- Rodríguez-Domínguez M, González-Alba JM, Puerta T, Menéndez B, Sánchez-Díaz AM, Cantón R, et al. High prevalence of co-infections by invasive and non-invasive *Chlamydia trachomatis* genotypes during the lymphogranuloma venereum outbreak in Spain. *PLoS One.* 2015;10:e0126145.
- Peuchant O, Touati A, Sperandio C, Hénin N, Laurier-Nadalié C, Bébéar C, et al. Changing pattern of *Chlamydia trachomatis* strains in lymphogranuloma venereum outbreak, France, 2010–2015. *Emerg. Infect. Dis.* 2016;22:1945–7.
- Parra-Sánchez M, García-Rey S, Pueyo Rodríguez I, Viciano Fernández P, Torres Sánchez MJ, Palomares Folia JC. Clinical and epidemiological characterization of lymphogranuloma venereum in southwest Spain, 2013–2015. *Sex Transm Infect.* 2016;92:629–31.
- Lara-Oya A, Navarro-Marí JM, Gutiérrez-Fernández J. *Actinotignum schaalii* (formerly *Actinobaculum schaalii*): a new cause of balanitis. *Med Clin (Barc).* 2016;147:131–2 [article in Spanish].
- Escobar-Sevilla J, Hidalgo-Tenorio C, Navarro-Marí JM, Gutiérrez-Fernández J. Proctitis in an HIV-infected male who have sex with men. *Med Clin (Barc).* 2016;146:468–9 [article in Spanish].
- Gutiérrez-Fernández J, Navarro-Marí JM. Estudio de agentes genitopatógenos; 2016. Available from: <https://doi.org/10.6084/m9.figshare.3469931.v1> [accessed 12.11.16].
- Meyer T, Arndt R, von Krosigk A, Plettenberg A. Repeated detection of lymphogranuloma venereum caused by *Chlamydia trachomatis* L2 in homosexual men in Hamburg. *Sex Transm Infect.* 2005;81:91–2.

10. López-Vicente J, Rodríguez-Alcalde D, Hernández-Villalba L, Moreno-Sánchez D, Lumberras-Cabrera M, Barros-Aguado C, et al. Proctitis as the clinical presentation of lymphogranuloma venereum, a re-emerging disease in developed countries. *Rev Esp Enferm Dig.* 2014;106:59–62.

Antonio María Caballero-Mateos^a,
Mercedes López de Hierro-Ruiz^a,
Mario Rodríguez-Domínguez^{b,c},
Juan Carlos Galán-Montemayor^{b,c},
José Gutiérrez-Fernández^{d,e,*}

^a Servicio de Aparato Digestivo, Complejo Hospitalario Universitario de Granada, Granada, Spain

^b Servicio de Microbiología, Hospital Universitario Ramón y Cajal e Instituto Ramón y Cajal de Investigación Sanitaria (IRYCIS), Madrid, Spain

^c CIBER en Epidemiología y Salud Pública, Spain

^d Servicio de Microbiología, Complejo Hospitalario Universitario de Granada-ibsGranada, Granada, Spain

^e Departamento de Microbiología, Universidad de Granada-ibsGranada, Granada, Spain

*Corresponding author.

E-mail address: josegf@go.ugr.es (J. Gutiérrez-Fernández). 2444-3824/

© 2017 Elsevier España, S.L.U. All rights reserved.

Superior mesenteric artery pseudoaneurysm fistulised to the small intestine in a pancreas–kidney transplant recipient: Can it be detected by capsule endoscopy?



Seudoaneurisma de arteria mesentérica superior fistulizado a intestino delgado tras un doble trasplante renopancreático: ¿puede ser diagnosticado por cápsula endoscópica?

Simultaneous pancreas–kidney transplantation (PKT) is the treatment of choice for patients with type 1 diabetes mellitus and end-stage renal disease. Gastrointestinal bleeding is an uncommon complication following pancreas–kidney transplantation (around 1%), but it is associated with high morbidity and mortality. Upper gastrointestinal bleeding related to gastric ulcers is more frequent than lower bleeding. The rupture of a pseudo-aneurysm of the graft, from splenic or gastro-duodenal artery, is a rare cause of obscure gastrointestinal bleeding in this group of patients.¹

Investigation of gastrointestinal bleeding in a pancreas–kidney transplant recipient includes initially an upper and/or lower endoscopy, followed for radiologic procedures as an abdominal computed tomography (CT) and a digital subtraction angiography (DSA).

Small bowel Capsule Endoscopy (SBCE) is an endoscopic tool for visualize small bowel and with a higher diagnostic yield in obscure gastrointestinal bleeding compared to radiologic procedures.^{2,3}

This is a case of a patient with previous simultaneous pancreas–kidney transplantation who presented an obscure gastrointestinal bleeding. Capsule endoscopy played an important role in the diagnosis and management.

A 53-year-old man underwent kidney–pancreas transplantation for type I diabetes mellitus and end-stage renal disease. After two years, he was admitted to the emergency room with 4 days of melena, without instability. Nasogastric lavage showed clear gastric content, with no blood. Hemoglobin level was 8.4 g/dl with normal platelet count and coagulation parameters. Upper gastrointestinal

endoscopy was performed showing a small sessile polyp lesion in antrum with no traces of blood.

After 24 h, the patient had a rebleeding episode and 4 blood units were transfused. After clinical stabilization colonoscopy was performed showing diverticulosis in the sigmoid colon and abundant blood traces. CT angiography (CTA) was performed showing a 2.3 cm pseudo-aneurysm at the anastomosis between the graft's pancreatic arteries and the recipient's common iliac arteries. There was no contrast extravasation into the intestinal lumen.

A Pillcam Small Bowel Capsule Endoscopy (SB2, Given Imaging, YoKneam, Israel) was administered, showing as the most important finding, a cavity located in medium jejunum (40 min after pylorus) where the capsule was retained for more than 3 h surrounded by several ulcerative lesions, mucosal erythema and neovascularization as well as a polypoid image that seemed to correspond to ampulla of Vater (Fig. 1). These findings suggested that the pseudo-aneurysm was fissuring the small bowel, so an urgent angiography was performed.

The angiography of the right common iliac artery confirmed a pseudo-aneurysm originated in the superior mesenteric artery (SMA) anastomosis (Fig. 2). Embolization of the aneurysmal sac was performed. First, two coils were placed in a branch of the SMA to prevent retrograde filling of the pseudo-aneurysm and later, detachable coils were used to treat the aneurysmal sac. The final angiography showed an 80% exclusion of the pseudo-aneurysm. Subsequent Doppler ultrasound and CTA confirmed its complete occlusion. Additionally, a mycotic aneurysm was ruled out after a labeled leukocyte scintigraphy.

The patient presented an excellent outcome, with no recurrent bleeding episodes, and was discharged in a week. After 1 year of follow-up the patient has not presented any rebleeding episode, Doppler ultrasound remains without changes, and the pancreas and kidney transplant continue to function properly.

This is a rare case of obscure gastrointestinal bleeding due to a donor pancreatic artery pseudo-aneurysm, complicated with an arterioenteric fistula.

There are few cases reported in the medical literature.^{4–7}

The pseudo-aneurysms are serious, usually late-onset complications, which could be located at any intraparenchymal artery of the graft, at the interposed arterial graft or at