

Significance of p53 expression in non-tumoral epithelium adjacent to oral squamous cell carcinomas

MIGUEL ANGEL GONZALEZ-MOLES, M.D., PH.D.^{*}, PABLO GALINDO, D.D.S., PH.D.[†], JOSE GUTIERREZ, M.D., PH.D.[‡], ALBERTO RODRIGUEZ-ARCHILLA, D.D.S., PH.D.^{*}, ISABEL RUIZ-AVILA, M.D., PH.D.^{**}, ELENA SANCHEZ-FERNANDEZ, M.D., PH.D.[†]

Abstract

Alterations of the p53 gene are the most frequently documented genetic abnormalities in human cancer. The aim of the present study was to analyse if this alteration is an early event in oral tumorigenesis and if the suprabasal expression of p53 is a marker of the presence and severity of epithelial dysplasia. Immunohistochemical p53 expression in 78 specimens of oral squamous cell carcinoma and non-tumoral adjacent epithelium was analysed. Non-tumoral epithelium was observed in 53 cases (67.9 per cent), being normal in six cases (7.6 per cent), hyperplastic in 24 cases (30.7 per cent) and dysplastic in 48 cases (61.5 per cent). Epithelial dysplasia was mild (23 cases, 47.9 per cent); moderate (23 cases, 47.9 per cent) and severe (two cases, 4.1 per cent). Twenty-one cases of the dysplasias (43.8 per cent) expressed p53. No p53 expression appeared in any normal epithelium. Basal p53 expression always appeared in mild dysplasias (two cases). Suprabasal p53 expression appeared in mild and moderate dysplasias in nine cases and in one severe dysplasia. No statistical correlation was observed between suprabasal expression of p53 and the presence or severity of the dysplasia. The expression of p53 is an early event in oral tumorigenesis but it does not behave as an objective marker of the presence or severity of epithelial dysplasia.

Key words: Mouth Neoplasms; Carcinomas, Squamous Cell; Genes, p53

Introduction

The p53 gene is a tumour suppressor that codifies a protein with a molecular weight of 53 kilo Daltons that can arrest the cell cycle at the late G₁ phase in cells with sub-lethal damage in their genome until their complete repair, or induce apoptosis in cases of irreparable injury.¹ Alterations of the p53 gene are the most frequently documented genetic abnormalities in human cancer.^{2,3} These alterations also seem to be related to the multi-step processes of oral carcinogenesis^{4–8} but some issues have yet to be elucidated. For example, it is not known whether p53 gene alterations are an early, or late, event in oral tumorigenesis.

Several authors^{4,9,10} considered the analysis of non-neoplastic epithelia adjacent to the oral cancer to be a good study model to determine whether p53 disorders occur early or late in the oncogenesis. They assumed that p53 alterations in these epithelia do not result from the inductive effect of the tumour but rather precede the development of the cancer. Regezi *et al.*¹¹ considered that if the epithelial expression of p53 is the result of a genetic mutation, the change is irreversible and thus indicative of

evolution to invasive carcinoma within an unpredictable period of time. In contrast, other authors^{12,13} pointed out that expression of p53 protein in epithelia with dysplasia could simply indicate that the p53 system is functioning correctly and is active in genetically stressed cells, which might from that point be repaired or brought to apoptosis, or might enter the cycle of malignant transformation.¹⁴ In normal conditions, the basal layer is the only epithelial site where cell proliferation is produced, while in suprabasal layers there is only maturation, so that the basal and suprabasal expressions of p53 probably have distinct implications. While the basal expression of p53 presumably responds to the accumulation of normally functioning wild-type protein, suprabasal expression could indicate the presence of mutated protein in DNA-damaged proliferative cells. If this is the case, as claimed by Cruz *et al.*,¹⁵ the suprabasal immunostaining of p53 protein could behave as an objective marker of the presence and severity of epithelial dysplasia, since it would appear in proliferative cells in epithelial layers where only maturation should exist. This is an important issue, since epithelial dysplasia is the

From the Departments of Oral Medicine^{*}, School of Dentistry, Oral Surgery[†], School of Dentistry, and Microbiology[‡], School of Medicine, University of Granada, and the Department of Pathology^{**}, Jaen General Hospital, Spain.
Accepted for publication: 4 December 2001.

most widely used indicator of precancerous lesions, despite the drawback that its assessment is highly subjective.^{16,17}

The present study aimed to analyse whether p53 expression is an early event in oral tumorigenesis and whether the suprabasal expression of p53 behaves as an objective marker of the presence and severity of epithelial dysplasia.

Material and methods

Stored formal-fixed paraffin-embedded surgical specimens were studied from 78 patients (mean age 62.7 ± 12.2 years) treated for intraoral ($n = 40$) and lip ($n = 38$) cancer at Granada University clinic hospital. A $5 \mu\text{m}$ section from each paraffin block was used for haematoxylin-eosin staining. In each sample the presence of non-neoplastic epithelium adjacent to the tumour was classified as normal, hyperplastic or dysplastic; the epithelial dysplasia was assessed as mild, moderate or severe according to the criteria of the single pathologist who performed the observation.

Immunohistory

A $3\text{--}5 \mu\text{m}$ tissue section of each paraffin block was used for the immunohistochemical analysis. After deparaffinization and dehydration, the endogenous peroxidase was blocked by incubation for 30 minutes in 0.3 per cent H_2O_2 in methanol. Non-specific binding was inhibited by incubation with 1:20 dilution of normal horse serum for 60 minutes. Sections were incubated in 1:50 and 1:100 dilution of monoclonal anti-p53 protein antibody Bp53-12 overnight at 4°C in a humidified chamber. Biotinylated anti-mouse IgG (Vector Lab., USA) was applied at a dilution of 1:200 for 30 minutes, followed by streptavidin peroxidase (Vector Lab., USA) at 1:100 for an additional 30 minutes. Finally, the peroxidase activity was developed by the 3,3'-diaminobenzidine hydrogen peroxidase reaction. Primary antibody was replaced by normal goat serum and a known p53-positive squamous cell carcinoma was used for negative and positive controls, respectively. Antigen retrieval methods were used in this study.¹⁸ The nuclear expression of p53 protein was assessed in the cells of non-tumoral epithelia adjacent to the cancer. The p53 protein staining was classified according to its presence in the basal layer and/or suprabasal layers; three categories were defined: no p53 expression,

nuclear staining confined to basal cells, and nuclear staining in suprabasal cells. The nuclear expression of p53 in the tumour was classified as negative (0 per cent p53-positive tumour cells), mild (<25 per cent), moderate (25–50 per cent) or extensive (>50 per cent p53-positive tumour cells).¹⁹ The degree of tumour differentiation was evaluated as well-differentiated (WD), moderately-differentiated (MD) and poorly-differentiated (PD).

Statistical analysis

The arithmetic means, standard deviations and percentages were determined. The Chi-squared test and the Spearman non-parametric correlation coefficient were applied when appropriate. $p < 0.05$ was considered significant.

Results

Non-tumoral epithelium adjacent to the cancer was observed in 53 (67.9 per cent) of the 78 tumours in the series. Normal epithelium was observed in six cases (7.6 per cent), hyperplastic epithelium in 24 cases (30.7 per cent) and dysplastic epithelium in 48 cases (61.5 per cent). The epithelial dysplasia was assessed to be mild in 23 cases (47.9 per cent), moderate in another 23 cases (47.9 per cent) and severe in two cases (4.1 per cent). No p53 expression appeared in any normal epithelium adjacent to the tumour. In adjacent hyperplastic epithelia there was no p53 expression in 18 cases, basal expression in one case and suprabasal expression in five cases. p53 expression in adjacent dysplastic epithelia is shown in Table I and Figure 1.

In the tumoral tissue, there was no p53 expression in 33 cases (44.6 per cent), mild expression in 15 (20.3 per cent), moderate expression in another 12 cases (16.2 per cent) and extensive expression in 14 cases (18.9 per cent). Tumours were WD in 30 cases (40.5 per cent), MD in 35 cases (47.3 per cent), and PD in nine cases (12.2 per cent). No statistically significant relationship was found between tumoral expression of p53 and degree of tumour differentiation. There was a statistically significant relationship between p53 expression in the tumour ($p < 0.05$). Thus, p53 expression appeared in more tumour cells when the adjacent dysplastic epithelium also expressed p53. There was no significant relationship between the suprabasal expression of p53 and the presence or severity of epithelial dysplasia in non-tumoral epithelia adjacent to the tumour.

TABLE I

EXPRESSION OF p53 PROTEIN IN DYSPLASTIC EPITHELIA ADJACENT TO THE TUMOUR ACCORDING TO THE SEVERITY OF THE DYSPLASIA AND THE BASAL OR SUPRABASAL LOCALIZATION OF THE IMMUNOSTAINING

	p53 +		p53 -	TOTAL
	Basal n (%)	Suprabasal n (%)	n (%)	
Normal epithelium	0 (0%)	0 (0%)	6 (11.8%)	6
Hyperplastic epithelium	1 (33.3%)	5 (20.8%)	18 (35.3%)	24
Mild dysplasia	2 (66.7%)	9 (37.5%)	12 (23.5%)	23
Moderate dysplasia	0 (0%)	9 (37.5%)	14 (27.5%)	23
Severe dysplasia	0 (0%)	1 (4.2%)	1 (1.9%)	2
Total	3 (100%)	24 (100%)	51 (100%)	78

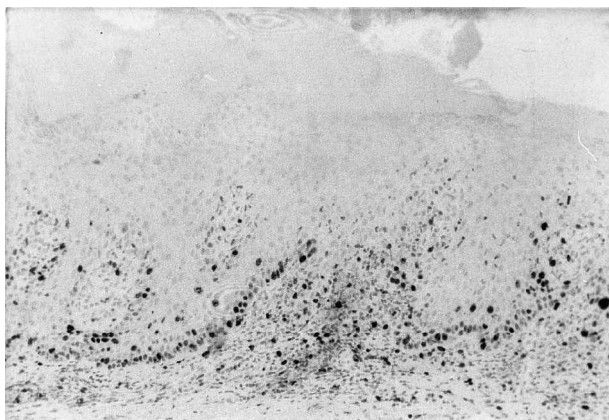


FIG. 1

Basal and suprabasal expression of p53 in dysplastic epithelium adjacent to tumour. (Peroxidase-antiperoxidase immunostaining; $\times 40$)

Discussion

In agreement with other researchers,^{4,9-11} we consider the analysis of non-tumoral tissue adjacent to the tumour to be a study model to determine whether p53 disorders occur early or late in oral tumorigenesis. In the present series, all normal epithelia adjacent to the tumour were p53-negative. p53 expression was detected in 25 per cent of cases of adjacent hyperplastic epithelia (six positive cases out of 24) and in 43.7 per cent of cases with mild, moderate or severe epithelial dysplasia adjacent to the tumour (21 cases out of 48). Other authors^{4,9-11} also found that the number of cases that expressed p53 increased as the epithelial disorder progressed from hyperplasia to epithelial dysplasia. All these studies concluded that the p53 alteration is an early phenomenon in oral carcinogenesis. In contrast, Piffko *et al.*¹³ concluded that in some of these positive cases the p53 expression could simply indicate that the p53 control system is functioning correctly and is active in some cells in response to genotoxic stress. This conclusion followed their observation of a higher percentage of positive cases in non-neoplastic epithelia adjacent to the tumour (77 per cent) *versus* those found in the tumour (40 per cent). In the present study, the number of cases that expressed p53 increased progressively with the severity of the epithelial disorder until the maximum percentage of positivity in tumour tissue was reached (54.4 per cent; 41 positive cases out of 78 tumours). We observed a significant correlation ($p < 0.05$) between p53 staining status in epithelia with dysplasia adjacent to the tumour and the extent of p53 disorder in the tumour itself. In our series, p53 expression appeared in more tumour cells when adjacent epithelium with moderate or severe forms of dysplasia also expressed p53. Thus, we consider that the alteration of p53 could be an early event in oral tumorigenesis and that p53 immunostaining in epithelia with dysplasia adjacent to the cancer could be an indicator of a greater p53 disorder in the tumour.

There are contradictory reports on the possible value of p53 expression as a marker of the presence and severity of epithelial dysplasia. Cruz *et al.*¹⁵ found no significant association between suprabasal p53 expression and the histological grade of the dysplasia. Regezi *et al.*¹¹ also found no association between the grade of the dysplasia and the percentage of p53-positive cells in premalignant oral lesions. In contrast, other authors²⁰ reported a significant correlation between p53 expression and the grade of the dysplasia. Our analysis showed no significant association between the suprabasal expression of p53 and the presence or severity of epithelial dysplasia in non-neoplastic epithelia adjacent to the tumour. The subjectivity implied in the assessment by different pathologists of the presence and severity of epithelial dysplasia may account for the variability in the above results.

To summarize, p53 expression in epithelia adjacent to the tumour may be an early event in oral tumorigenesis and p53 expression in dysplasias of these epithelia may behave as a marker of greater p53 alteration in the tumour. Finally, the suprabasal expression of p53 was not an objective marker of the presence or severity of epithelial dysplasia.

References

- 1 Cordon-Cardo C. Mutation of cell cycle regulators. Biological and clinical implications for human neoplasia. *Am J Pathol* 1995;**147**:545-60
- 2 Nigro JM, Baker SJ, Preisinger AC, Jessup JM, Hostetter R, Cleary K, *et al.* Mutations in the p53 occur in diverse human tumour types. *Nature* 1989;**342**:705-8
- 3 Hollstein M, Sidransky D, Vogelstein B, Harris C. p53 mutations in human cancers. *Science* 1991;**253**:49-53
- 4 Warnakulasuriya KA, Johnson NW. Expression of p53 mutant nuclear phosphoprotein in oral carcinoma and potentially malignant oral lesions. *J Oral Pathol Med* 1992;**21**:404-8
- 5 Kusama K, Okutsu S, Takeda A, Himiya T, Kojima A, Kidokoro Y, *et al.* p53 gene alterations and p53 protein in oral epithelial dysplasia and squamous cell carcinoma. *J Pathol* 1996;**178**:415-21
- 6 Crosthwaite N, Teale D, Franklin C, Foster GA, Stringer B. p53 protein expression in malignant, premalignant and non-malignant lesions of the lip. *J Clin Pathol* 1996;**49**:648-53
- 7 Stoll C, Baretton G, Lohrs U. The influence of p53 and associated factors on the outcome of patients with oral squamous cell carcinoma. *Virchows Arch* 1998;**433**:427-33
- 8 Gulley ML, Burton MP, Allred DC, Nicholls JM, Amin MB, Ro JY, *et al.* Epstein-Barr virus infection is associated with p53 accumulation in nasopharyngeal carcinoma. *Hum Pathol* 1998;**29**:252-9
- 9 Shin DM, Kim J, Ro JY, Hittelman J, Roth JA, Hong WK, *et al.* Activation of p53 gene expression in premalignant lesions during head and neck tumorigenesis. *Cancer Res* 1994;**54**:321-6
- 10 Lavieille JP, Brambilla E, Riva-Lavieille C, Reynt E, Charachon R, Brambilla C. Immunohistochemical detection of p53 protein in preneoplastic lesions and squamous cell carcinoma of the head and neck. *Acta Otolaryngol* 1995;**115**:334-9
- 11 Regezi JA, Zarbo RJ, Regev E, Pisanty S, Silverman S, Gazit D. p53 protein expression in sequential biopsies of oral dysplasias and *in situ* carcinomas. *J Oral Pathol Med* 1995;**24**:18-22
- 12 Hall PA, Lane DP. p53 in tumour pathology: can we trust immunohistochemistry?-revisited! *J Pathol* 1994;**172**:1-4

- 13 Piffko J, Bankfalvi A, Ofner D, Berens A, Tkotz T, Joos U, *et al.* Expression of p53 protein in oral squamous cell carcinomas and adjacent non-tumorous mucosa of the floor of the mouth: an archival immunohistochemical study using wet autoclave pretreatment for antigen retrieval. *J Oral Pathol Med* 1995;**24**:337–42
- 14 Levine AJ, Momand J, Finlay CA. The p53 tumour suppressor gene. *Nature* 1991;**351**:453–6
- 15 Cruz IB, Meijer CJ, Snijders PJ, Snow GB, Walboomers JM, van Der Waal I. p53 expression above the basal cell layer in oral mucosa is an early event of malignant transformation and has predictive value for developing oral squamous cell carcinoma. *J Pathol* 1998;**184**:360–8
- 16 Kramer IRH. Basic histopathological features of oral premalignant lesions. In: Mackenzie IC, Dabelsteen E, Squier C, eds. *Oral Premalignant Lesions*. Iowa: University of Iowa Press, 1980;23–4
- 17 Karabulut A, Reibel J, Therkildsen MH, Praetorius F, Nielsen HW, Dabelsteen E. Observer variability in the histologic assessment of oral premalignant lesion. *J Oral Pathol Med* 1995;**24**:198–200
- 18 Li X, Tsuji T, Wen S, Sobhan F, Wang Z, Shinozaki F. Cytoplasmic expression of p53 protein and its morphological features in salivary gland lesions. *J Oral Pathol Med* 1995;**24**:201–5
- 19 Gonzalez-Moles MA, Galindo P, Gutierrez-Fernandez J, Sanchez-Fernandez E, Rodriguez-Archilla A, Ruiz Avila-I. p53 protein expression in oral squamous cell carcinoma. Survival analysis. *Anticancer Res* 2001;**21**:2889–94
- 20 Wood MW, Medina JE, Thompson GC, Houck JR, Min KW. Accumulation of the p53 tumor-suppressor gene product in oral leukoplakia. *Otolaryngol Head Neck Surg* 1994;**111**:758–63

Address for correspondence:
Miguel Angel Gonzalez-Moles,
Medicina Oral,
Facultad de Odontologia,
Colegio Maximo s/n Campus de Cartuja,
Univ. de Granada,
E-18071-Granada,
Spain.

Fax: +34 958 244085
E-mail: magonzal@ugr.es

Professor M. A. Gonzalez-Moles takes responsibility for the integrity of the content of the paper.
Competing interests: None declared
