

Anthropological identification and paleopathological study of a skeleton, probably pertaining to the Roman doctor from the I-II century b.C., Tiberius Claudius Apollinaris (Tarragona, Spain)

DOMINGO CAMPILLO (*)

FRANCESC TARRATS (**)

SUMMARY

Aim of the study. Historical new. Study of the individual in tomb n.º 2 at «Robert d'Agui-lo» street (Tarragona). Anthropological study. Anthropological summary. Pathology study. Pathologic conclusions. Comparative study between the cranium and the head of the bust. Similar studies. Bibliography.

RESUMEN

Hemos realizado el estudio antropológico de un esqueleto procedente de una tumba romana del siglo I-II a.C., con la finalidad de constatar si la morfología del cráneo se correspondía con la de un busto intimamente relacionado con su tumba, que por una serie de circunstancias arqueológicas, parecía corresponder a un médico de época romana.

Después del estudio antropométrico, craneográfico y patológico, llegamos a la conclusión de que los restos exhumados eran compatibles con la morfología del busto, con lo que se reafirma el criterio arqueológico de que probablemente, se trata del médico tarraconense Tiberius Claudius Apollinaris.

Fecha de aceptación: 15 de mayo de 1991.

(*) Professor of the Autonomic University of Barcelona and Head of the Laboratory of Paleoanthropology and Paleopathology of the Archeological Museum of Barcelona.

(**) Director of the National Archeological Museum of Tarragona.

DYNAMIS

Acta Hispanica ad Medicinae Scientiarumque Historiam Illustrandam. Vol. 11, 1991, pp. 387-414.

ISSN: 0211-9536

AIM OF THE STUDY

In view of the archeological findings and of some skeletal remains which appeared to be correlated between each other, some doubts arose as to whether the bust corresponded to the individual mentioned on the funeral plate and to the skeleton deposited inside the sarcophagus. With the aim of attempting to clarify this problem, we proposed an anthropological study of the skeleton, with the aim of verifying whether the cranean morphology and the individuals's constitution were compatible with the morphological characteristics of the person represented in the bust. Our study has been completed with the paleopathological investigation which could also have had a certain influence on the individual's physical aspect.

In view of the results obtained, we consider it of interest to present our study, as there are few similar paleopathological papers in the literature.

HISTORICAL NEWS

In 1713, Iosep Boy, an engineer from the city of Tarragona, Spain, recovered a funeral inscription dedicated to Tib(erius) Cl(audius) Apollinaris artis medicin(a)e doctiss(imus). This gravestone was located by the author of this compilation set into one of the walls of the city recinct, although it no longer exists, constituting the first historical testimony of the practice of medical science in Tarragona. Later, the archeological excavations which have been carried out in the ancient city of Tarraco, especially since the middle of the XIX century have led to the recuperation of several bronze instruments related with the said profession. But the inscription is still the only personalised source of information in relation to this activity.

The site at which Boy located the inscription clearly indicates that the piece was transported to be reused as construction material in the reforms which were introduced into the walled recinct and which came from a necropolis of the roman city, almost without doubt close to the point at which the gravestone was reused.

Thanks to the picture and to the description that the engineer Boy legated the chronology of the piece has been determined fairly precisely. Géza Alföldy situates it around the I or II century b.C. It corresponds to a funeral inscription belonging to the Hight Empire. Present-day knowledge of the roman city of Tarraco leads us to deduce that this gravestone could only

have been extracted from the necropolis existing near the old Via Augusta, relatively close to the section of wall where we believe it was later re-used according to the data provided by Boy.

In the year 1978, during a series of emergency archeological excavations performed in this sector of the necropolis, as a consequence of the Robert D'Aguiló Street urbanization, amongst other remains a stone sarcophagus containing human remains accompanied by a rich array of associated funeral objects composed of: 16 glass ointment flasks, 1 small glass bottle, 1 bone box, 1 flattened marble stone («*cotricula*»), 1 bronze needle, 1 bronze quadrangular shaped mirror, remains of a bone comb, bronze frameworks and other elements of the same metal were found, possibly belonging to a wooden box, 1 bronze coin (dupondi) from the Tarraco mint, an issue from the era of Tiberio.

Some of the elements of the complex funeral objects (bone box, *cotricula* and the bronze needle especially) appear to be related with a person linked to the practice of medicine.

Closed to the interment a marble funeral bust was encountered, representing a person with a beard, dated to the second half of the I century b.C. (fig. 5 and 6).

The data revealed lead us to attempt to establish the hypothesis of a possible connection between the three archeological settings just presented: Inscription compiled by Boy, bony remains and funeral objects contained within the sarcophagus, and lastly, the funeral bust.

Topographically no contradictions exist. Chronologically a coincidence exists between the dates attributed to the funeral bust and to the inscription. With regard to the associated funeral objects the only component which could be out of place is the coin, dated without any doubt in the era of Tiberio. In our opinion, its presence in the interment implies no problems as it was probably considered a coin of prestige from a collection no longer in circulation, which does not impede one giving the interment a later chronology.

STUDY OF THE INDIVIDUAL IN TOMB Nr.2 AT «ROBERT D'AGUILO» STREET (TARRAGONA)

An almost complete, fairly well preserved skeleton was encountered with a conservation index of 59, in which almost all the bones of the hands and

feet were missing. The ribs have several fractures incurred posthumously and some epiphyses are slightly damaged.

The whole skeleton is grey colored attributable to the earth in which it was deposited which left a thin layer of concretions.

Although the number of preserved bones is very important, the bony structure was weak due to taphonomic processes. In order to favour preservation we proceeded to submerge the bones in a 10% solution of «Paraloid» in toluene. The cranium, in the right parietotemporal region presented a posthumous fracture with loss of some fragments of bone, as well as other small areas which were dereriorated and required restoration with «poliester» carried out by Mr. Jaume Mayas and assistants.

Anthropological study

(According to Martin's and Saller's technique)

CRANIUM

The complete cranium is in a fairly good state of preservation, with an inferior fragment of the right parietal bone missing, wich includes the pterigoid region of the occipital and temporal bones with the mastoid process of the same side. The left condyle of the mandible is missing as well as all the teeth, although some were lost during the individual's lifetime.

ANTHROPOMETRY

Neurocranium

Thickness of the parietal bones to the protuberances.....	8 mm
Maximum length.....	180 mm
Maximum width.....	150 mm
Length of base of the cranium.....	97 mm
Minimum frontal width.....	98 mm
Basilar height (Basio-Bregma).....	121 mm
Auricular height (Porion-Bregma).....	111 mm
Maximum horizontal circumference.....	528 mm

Transverse arch (Porion-Bregma-Porion).....	315 mm
Sagittal arch	371 mm
Frontal sagittal arch.....	121 mm
Parietal sagittal arch.....	135 mm
Occipital sagittal arch.....	115 mm
Sagittal arch of the squamous occipital.....	65 mm
Frontal sagittal chord.....	114 mm
Parietal sagittal chord.....	118 mm
Occipital sagittal chord.....	96 mm
Sagittal chord of the squamous occipital.....	62 mm
Cranial capacity.....	1.521 cc

Splanchnocranium

Length of the face.....	94 mm?
Bizygomatic width.....	137 mm
Total height of the face.....	118 mm??
Height of the superior face.....	74 mm
Orbital width.....	41 mm
Orbital height.....	38 mm
Interorbital width.....	19 mm
Biorbital width.....	91 mm
Nasal width.....	24 mm
Nasal height.....	35 mm?
Maxiloalveolar length.....	54 mm??
Maxiloalveolar width.....	69 mm
Length of the palate.....	46 mm
Width of the palate.....	39 mm

Mandible

Bicondylar width.....	128 mm
Bigonid width.....	107 mm
Total length of the mandible.....	106 mm
Height of the ramus of the mandible.....	67 mm
Width of the mandibular ramus.....	32 mm

Cranial indices

Cephalic.....	83.33
Basilar height/length.....	73.33
Basilar height/width.....	88.00
Mean basilar height/length-width half-sum.....	80.00
Auricular height/length.....	61.66

Auricular height/width.....	74.00
Mean auricular height/length-width half-sum	67.27
Total facial.....	86.13
Superior facial.....	54.01
Transverse craneo-facial.....	91.33
Transverse frontal.....	80.91
Fronto-parietal.....	65.33
Orbital.....	92.62
Nasal.....	43.63
Flower's gnathic index	96.90
Mandibular.....	82.81

DESCRIPTIVE FEATURES (Fig. 1 and 2)

The prominences for muscle insertions are moderate, even though posthumous deterioration and weathering make their evaluation difficult. Synostosis is total in the endocranium, whilst in the exocranium all the sutures were free, except sectors S3 and S4 of the interparietal suture. The degree of complexity the sutures is average.

Seen from the superior view, the cranial outline is spheroid according to Sergi's classification, with not very prominent frontal and parietal protuberances. Moderate phenozygia (in Figure n.º 2, in the photographic craneogrammes the phenozygia disappear due to photographic distorsion) with gracile zygomatic arches.

The lateral view shows rounded cranium from just after sector M2 of the frontal bone, with the glabella and the supraciliary arches corresponding to types IV and Broca's grade «2» external occipital protuberance. The face is almost flat with the nasal bones protruding. The nasal spine is not very prominent. The Pterion is «H» shaped, Martin's «e» type. The mastoid process is large and robust.

From the front, the forehead is narrow (index, 65.33) with not very marked protuberances and the face has an average width (index 86.13) with quadrangular orbits with rounded angles. The nasal fossa is piriform in shape with a moderate prenasal vestibule, the nasal bones having a Martin's type «1» morphology. Glabellar metopism. Robust cheekbones with a deep De Villiers type «3» canine fossa. The protuberance at the roots of the teeth is very moderate.

The posterior view shows a dome-shaped form with a rounded superior outline. Deterioration makes assessment of the nape lines difficult but they appear to have had moderate prominences. The presence of three small supernumerary bones was observed in the lambdoid hemisuture.

The inferior aspect shows a «U» shaped dental arcada with a shallow flattened palate. The foramen magnum is almost circular with middle sized condyles. The glenoid cavities are deep and narrow.

The mandible is fairly robust, with a not too prominent chin (Fig. 3) but with a well marked mentonian protuberance. The mental foramen are situated vertical to P2 at a half height. The spina musculi genio hyoidei are represented by two fairly prominent superior tubercles and another inferior one between them. The ramus are wide with a wide and narrow right condyle (the only preserved) with the superior edge angled. The incisura mandibulae is not very deep and the coronoid process is wide and not too pointed with the tip in a slightly backward direction. Spix's ossicle is small with a large dental foramen.

DENTAL STUDY (by Dr. Eduard Chimenos)

Not one tooth has been preserved. Reabsorption of alveoli 17, 18, 26, 27, 35, 36, 37, 45 and 46 has occurred.

Maxillar teeth

Apparent flattening of the alveolar margin (palatine depth 9 mm), we suspect that this was caused by a loss of bony support due to periodontitis, possibly potentiated by caries. To the vestibular wall corresponding to nr. 15 the individual had probably undergone an infectious disorder which drained to the exterior and destroyed the alveolar wall. Teeth 17 and 18 were almost certainly lost antemortem as the alveolar bone seems to have partially remodelled, with elimination of the corresponding alveolar spaces.

Mandible

The appearance of the region of the anterior alveolar process, between the two first inferior premolar teeth, lead one to believe that all these pieces

remained *in situ* until the individual's death, eventhough they must have been affected by a moderate periodontal disease (periodontitis) with a slight loss of bony support.

On the right side, teeth 45 and 46 were probably lost long before death, the alveolar bone having completely regenerated. On the left, teeth 35, 36 and 37 were lost antemortem, the alveolar bone also completely regenerating.

POSTCRANIAL SKELETON

No remarkable features of an anthropological nature can be described in the postcranial skeleton, as the alterations observed are anomalies and pathological alterations wich will be studied later. The study is completed by anthropological data.

ANTHROPOMETRY AND INDICES

<i>Scapula</i>	<i>Right</i>	<i>Left</i>
Height.....	160160 mm.??
Width.....	113117 mm.
Glenoid height.....	41? 40 mm.?
Glenoid width.....	32 mm.
Scapular index.....	70.62 73.12
 <i>Ulna</i>		
Antero-posterior diametre.....	26 26 mm.
Transverse diametre.....	20 mm.
Maximum length.....	—255 mm.
Physiological length.....	—236 mm.
 <i>Radius</i>		
Sub-occipital circumference.....	45 45 mm.
Maximum transverse diametre.....	16 16 mm.
Minimum transverse diametre.....	14 13 mm.
 <i>Hip joint</i>		
Maximum height.....	220220 mm.?
Hip width.....	190? mm.
Iliac width.....	168?168 mm.??
Ilium height.....	141141 mm.?

<i>Hip joint</i>	<i>Right</i>	<i>Left</i>
Length of the Ischium.....	88	90 mm.?
Length of the pubis.....	73	81 mm.??
Cotylo-sciatic width.....	40	38 mm.
Iliac width index.....	114.18	—
Schultz ischio-pubic index.....	91.25	—
 <i>Femur</i>		
Physiological length.....	434	mm.
Maximum length.....	438	mm.
Trochanter length.....	421	421 mm.
Transverse diametre midway up the epiphisys.....	30	30 mm.
Antero-posterior diametre midway up the epiphisys.....	31	31 mm.
Width of the inferior epiphysis.....	85	81 mm.?
Subtrochanteriam transverse diametre.....	30	31 mm.
Tibio/femoral crural index.....	87.55	—
 <i>Tibia</i>		
Total length.....	380?	380 mm.
Superior epiphyseal width.....	74	76 mm.
Transverse diametre.....	24	25 mm.
Antero-posterior diametre.....	40	38 mm.

Anthropological summary

DETERMINATION OF AGE

Although consolidation of the cranial sutures is not too advanced considering the marked osteo-arthritic alterations encountered which in part could be related to his traumatic lesions, in our opinion the individual was an adult probably mature in age. The presence of the thyroid cartilage in an advanced stage of calcification supports our opinion.

DETERMINATION OF SEX

In the cranium, the supraciliary archs and the robustness of the mastoid processes favour the male sex, a criterion which is supported by the 60.° subpubic angle, Schultz' ischio pubic index (91.25) and the width of the inferior epiphysis of the right femur (85 mm).

DETERMINATION OF HEIGHT

In order to determinate this individual's height we have used Manouvrier's and Trotter-Gleser's tables applied to the femurs and to the femur-tibia and have reached the conclusion that the height ranged from 165-169 cm.

TYPOLOGY

The morphology of the spheroidal cranium, wide, globulous brachicranium (index 83.33) with patinocranium (index 88.00), the squamous occipital bone curved with a rounded occiput, the glabella and the supraciliary archs are moderately prominent, the face is fairly wide with a wide mandible (index 82.81). The face is flat with prominent cheek-bones, the nasal bones are straight, the orbits quadrangular and the chin is small.

Likewise, the corporal height is average with wide shoulders and short limbs, features compatible with the alpine typology (brachicephalous curved occipital bones) according to Ferembach's classification.

Pathology study

As the anomalies and pathological alterations are numerous, an anatomical order will be followed to describe them, ending the discussion with an interrelation between same which allow us to reach aetiogenic conclusions.

CRANIUM

We only find dental pathology included within the anthropological study.

SPINE AND THORAX

Almost all the spine is preserved. The axis and vertebral bodies of C-3, T-9, T-10 and L-1 are missing.

The signs of osteoarthritis are marked along the whole of the spine.

At cervical level an osteophytic reaction exists on the articular surface of the anterior arch of the atlas at odontoid peg of the axis. All the joints show exostosis and the bodies are deformed, with an osteophytic edge reaction (grade «3» according to Stewart's classification), mainly affecting the last four vertebrae of the sector.

In the thoracic spine the osteoarthritic signs are moderate in the first three vertebrae (grade «1»). In the section involving T-4 to T-8 the alterations are intense, with large «parrot-beaks» (grade «4») plus synostosis of the bodies of T-5, T-6, and T-7, that of T-4 with T-5 and T-7 with T-8 are about to join. Unfortunately the bodies of T-9 and T-10 have been lost. In T-11 the osteoarthritic reaction is moderate (grade «1»), but the upper edge of T-12 has grade «3» alterations with a Schmorl's hernia which reaches the vertebral foramen, the vertebral body presenting a cuneiform morphology with a posterior base when it is observed laterally. The alterations of T-12 mentioned lead one to believe that a traumatic lesion of the vertebra occurred due to hyperflexion, probably with extrusion of the nucleus pulposus to the interior of the spinal canal. A herniated disc at this level is not very frequent, but it is not exceptional. Unfortunately, the body of L-1 has been lost and does not allow for a more precise evaluation.

The lumbar spine has only four vertebrae, as L-5 is sacralized. The body of L-1 as we have already mentioned, has been lost and L-2, L-3, and L-4 show moderate (grade «2») signs of osteoarthritis.

The sacrum is formed by six totally synostosed vertebrae. The signs of osteoarthritis at the basand at the small joints are very moderate. On the posterior face the foramina sacralis dorsalis are large and deep. The articular facets of the hip bones show a marked edge (the left one is almost destroyed).

There are no important lateral flattenings of the vertebral bodies to make one suspect a scoliosis.

Although there are many fractures *post mortem*, the majority of the ribs are preserved most of which show signs of osteoarthritis on the articular facet at the transverse process and the head of the rib. Two fragments of rib which could be fourth and a seventh one, show consolidated fractures with a bone callus.

Of the sternum only the manubrium is preserved which is rather deteriorated but which presents a typical sternocondral Srb anomaly (1862) (Fig. 4)

and which according to Köhler and Zimmer (1959) consists of a «regression of the first or of the first two ribs due to partial fusion of both in small bony horn». The articular facet on the internal epiphysis of the left clavicle shows marked signs of osteoarthritis (the external epiphysis is damaged).

A hyoid horn is also preserved and the thyroid cartilage partially calcified.

UPPER LIMBS

Of the clavicles the left is the only one preserved, with both epiphyses very much deteriorated, presenting in the middle portion a fairly large bone callus from a fracture which has consolidated well with no desviation and which implies prolonged survival after the trauma.

The scapulas present osteoarthritic edges at the glenoid cavities. The humerus and the ulna show signs of osteoarthritis at the epiphysis, somewhat more marked at the left ulna. The radii cannot be assessed due to posthumous deterioration and no alterations have been observed in the few remaining bones of the hands.

LOWER LIMBS

Hip bones

The subpubic angle has been calculated as being 60.º at it is difficult to measure due to deterioration of the symphysis facets, which also makes age assessment difficult.

The morphology of the right hip (the left is more deteriorated and deformed) is male and this is supported by the width indices of the iliac wing and of Schultz's ischiopubic index. As pathologic alterations, moderate signs of osteoarthritis can be observed at the cotyloid cell, at the descending ramus of the pubis and at the two rami of the ischium especially at the point of insertion of the gemelli pelvis at the tubercle of the ischium.

The left hip presents a severe traumatic lesion which, according to Judet and Letournel's classification (1974) would correspond to «the anterior spine», without a fracture of the middle ischiopubic ramus, associated with a fracture of the iliac wind.

DESCRIPTION OF THE FRACTURE OF THE LEFT HIP

Unfortunately, the iliac crest and the region of the articular facet are damaged and an accurate assessment cannot be made.

On the external face, a well consolidated fracture juts out from the superior angle of the obturator foramen, surrounds the condyloid cavity and penetrates through the angle of the greater sciatic notch. In the depths of the acetabulum a diastasis of the margins of fracture exists with a cicatrical exostotic reaction. Outside the cotyloid cavity, to the external part and extending itself up to the angle of the said sciatic notch, the presence of an exostotic pyramid which contacts the greater trochanter can be observed. Another fracture emerges from the external edge of the acetabulum and rises until it reaches the middle of the two antero and postero-superior iliac spines. Cicatrization is defective, a diastasis has formed as newly formed bone bridges.

On the internal face, the fracture follows the innominate crest and innumerable newly formed vascular orifices or possibly the result of a cured supuration can be seen.

As a result of these lesions, the cotyloid cavity has deepened and the iliac wing has undergone a downward deviation, adopting a more horizontal position.

The deformity of the left half of the pelvis is evident and undoubtedly it bears a relationship to a fracture of the left femur which will be commented on below.

The osteoarthritic exostoses are more evident at the pubis and ischium on the right side.

FEMURS

In both femurs, the linea aspera is highly marked. In the right femur a moderate exostosis can be observed at the superior margin of the greater trochanter and to vertex of the trochanter minor and a crest at both condyles.

The left femur lacks almost all the neck and the head of the femur, it not being at all easy to give an opinion on a probable post-traumatic necrosis of

the head of the femur, but if one considers the morphology of the acetabulum, we believe that the loss of the head was postmortem. To the superior edge of the greater trochanter a newly formed articular facet exists which formed a joint with the pathologic exostosis which has already been described. The signs of osteoarthritis are slightly more evident than on the right. In our opinion the neck of the femur was fractured, probably becoming engaged into the head which did not necrose but which allowed the greater trochanter to ascend giving rise to the formation of an anomalous joint.

TIBIAS

Both tibiae show signs of osteoarthritis in the form of a border around the glenoid cavities. The right side also shows osteophytes along the external half of distal articular face but we do not know whether they were also present on the left as the distal epiphysis is markedly deteriorated. The anterior tubercle of the left tibia is very prominent with superior osteophytes and they appear to be secondary to an Osgood-Schlatter lesion in his youth.

BONES OF THE FEET

The right calcaneum is very damaged and allows no type of evaluation. The left astragalus, the only bone preserved from the left foot, shows an important flattening of the head, which on the superior half which is preserved, presents a fairly important osteophytic crown. The right metatarsal bones show marked signs of osteoarthritis, especially evident in the first metatarsal bone above all at the level of its distal epiphysis.

Pathologic conclusions

1) ANOMALIES

In our opinion the sacralization of the fifth lumbar vertebra and Serb's sternal anomaly, were probably symptomfree.

2) TRAUMATIC LESION

This individual of robust constitution suffered, probably during his youth, a severe accident which caused several fractures: left clavicle, the

twelfth thoracic vertebra, the coccyx and left femur. It seems probable that all these lesions were secondary to a fall on the feet from considerable height. The impact of the femur broke the acetabulum with fissures irradiated to the rest of the coccyx, associated with a hyperflexion of the dorso-lumbar spine with anterior flattening of T-12 and fracture on protecting himself from the fall to the ground with his arm.

Undoubtedly, the fracture of the coxo-femoral joint gave rise to a marked limp and a lesion was also caused, at least partially, to the sciatic nerve. The fracture of the clavicle cured correctly and probably caused no posterior discomfort. With regard to the fracture of T-12, it could either have been symptom-free or have caused pain, disorders of the bladder sphincter and even a paraplegia but, as there was prolonged survival, we believe that the bony alterations of the lower limbs would have been more severe in the case of a paraplegia, a possibility which we almost rule out. The rib fractures would have been caused during the same accident, curing perfectly.

3) OSTEOARTHRITIC ALTERATIONS

They are frankly evident and very severe and in part, most probably, they were increased due to the alteration of deambulation as a result of the traumatic coxofemoral sequelae. We are sure that in order to walk he used a stick and the use of crutches cannot be ruled out.

4) DENTAL ALTERATIONS

Probably they were secondary to the diet and to a secondary periodontitis.

5) CAUSE OF DEATH

None of these lesions directly justify the cause of death; for this reason we cannot give an opinion.

COMPARATIVE STUDY BETWEEN THE CRANIUM AND THE HEAD OF THE BUST

In our paper we have attempted to make a careful comparative study between the cranium of the individual found in «tomb nr. 2» of Robert d'Aguiló Street and the head of the «bust of an unknown Individual» which one supposes represents the individual in the exhumated skeleton (Figs. 5 and 6).

Technique employed

We considered that the study was to be based on a correlation between the cranial measurements and those of the head of the bust (anthropometric study), proceeding also to a morphological comparison between the craneogrammes with their different views (Fig. 1 and 2) and the photographs of the head of the bust in anthropometric projections, following Frankfurt's sagittal and transverse planes (Fig. 7).

Anthropometry

PRINCIPAL ANTHROPOMETRIC PROBLEMS

- 1) The bust's head has a volume superior to that of the individual, which we have evaluated as being approximately 13 to 14% greater.
- 2) The epicranial tissues and the hair modify the craniofacial dimensions by increasing them.
- 3) The head is lightly deteriorated, the right ciliary region is broken as well as the left although only slightly, the nose is missing as well as the crown.
- 4) Eventhough it seems that the roman sculptors had a good realist school and obtained great resemblances, we are not sure about the faithfulness of the work.

CRITERION TO RESOLVE THE ANTHROPOMETRIC PROBLEMS

1) We have made an approximate calculation of the thickness of the hair which we have assessed as being about 15 mm and which we have deducted on taking the measurements.

2) The thickness of the epicranial teguments have not been taken into account because they represent a more or less uniform increase which cannot ostensibly modify the measurement. The beard is very short and hardly deforms the image. The greatest modifications correspond to the face, especially due to the individual being slightly obese. The nasal morphology has not been able to be taken into consideration.

3) We have taken the cranial and facial measurements which we have considered most trustworthy and with them have obtained the corresponding indices which are reflected in the following table.

<i>MEASUREMENTS:</i>	<i>Cranium</i>	<i>Head-Bust</i>
Maximum length.....	180 mm.	205 mm.
Maximum width.....	150 mm.	165 mm.
Auricular height.....	111 mm.	125 mm.*
Total height of the face (nasio-gnation).....	118 mm.	127 mm.
Bizygomatic width.....	137 mm.	148 mm.

* Measurement obtained by applying the Pythagorus theorem, on the rectangular triangles, by using the formula: $H^2 = C^2 + C^2$.

<i>INDICES:</i>	<i>Cranium</i>	<i>Head-Bust</i>
Cephalic.....	83.33 brachicranium	80.48
Auriculo-longitudinal.....	61.66 orthocranium	61.95
Auriculo-width.....	76.96 tapinocranium	76.96
Auriculo/mean.....	67.27 low ; average	68.64**
Total facial height/bizygomatic.....	86.13 mesoprosopie	85.81

RESULTS

If the proportions of the bust head with regard to the cranium were totally proportionate, the indices would have been identical but this must be considered as highly improbable, however meticulous the artist had been. In any event, one can see now almost all the indices correspond to the

same typology, except the «aricular)mean width+length» index is «average» (68.64**), but is almost at the highest level of the low results (68.00). In conclusion, we consider that from the anthropometric point of view the cranium and the head are compatible.

PRINCIPAL PROBLEMS

1) The head of the bust is in an oblique position leaning towards the left and with a slight rotation towards the same side. This position means that Frankfurt's plane is not parallel to the ground and for this reason it becomes difficult to centre the photographic camera.

2) determination of Frankfurt's plane is complex as the left infraorbital point and both porions are difficult to determine. The porions do not coincide exactly with the superior part of the external auditive canal. The incongruence between Frankfurt's true plane and that which we have calculated approximately, affects the anthropological «views» specially the antero-posterior one.

3) Photographic distorsion makes the photographic craneogrammes not completely superimposable with those drawn with the craneograph and with Martin's craneophor (Figs. 1 and 2). Although the photographs of the head of the bust have all been taken from the same distance, the focusing point is rather subjective, especially in the frontal view and small variations in the distance modify the distorsion.

TECHIQUE EMPLOYED

We have superimposed all the cranial views with those of the head of the bust, taking into account the approximate thickness of the teguments and of the hair and altogether we believe that they match correctly (Figs. 8 and 9) with the exception of the forehead, more affected by the non-correction of Frankfurt's plane and the photographic distorsion.

RESULTS

Even when taking into account the possible anomalies of any artistic reproduction, we considerer that the craneogrammes of individual nr. 2 of

«Robert d'Aguiló Street» are compatible with the morphology of the sculptured head which it is supposed belongs to it.

FINAL CONCLUSIONS

1) The morphology of the cranium is totally compatible with the head of the sculpture.

2) The pyknic aspect is also compatible with its anthropological morphology.

3) The obesity could have been influenced by the difficulties for deambulation, by the post-traumatic limp which would have forced him to a certain degree of sedentariness.

4) The age is difficult to assess. The aspect of the head of the bust seems to be that of an individual slightly younger but, apart from the possible modifications made by the artist, the osteoarthritic alterations lead one to believe he was a mature man, but they may also have been influenced indirectly by the severe fracture of the left lower limb. The possibility exists that the bust was made during a period well before death. Lastly, we must emphasize that we consider the skeleton to be between 45 and 55 years of age.

SIMILAR STUDIES

Exhaustive research of the literature has not been carried out but some papers have been found published by Genna (1958), Bartucz (1966) and Lengyel (1976), in which the skeletal remains of several known persons have been studied which are compared with their artistic representations, paintings and sculptures.

FINAL COMMENTS

On terminating this paper we consider it necessary to insist on the fact that it is not possible to reach more than a simple hypothesis, starting from an unquestionable fact. Tiberius Claudius Apollinaris is, up to the present, the first known doctor from Tarragona.

ACKNOWLEDGEMENTS

This paper would not have been possible without the meticulous collaboration of the Photographers Mr. Oriol Clavell and Julià Martínez. I would also like to thank Mrs. Antonia Grau for help with the drawings and also the restoration of the cranium carried out by Mr. Jaume Mayas and his associates. For other concepts I would like to express my gratitude to Mr. Joseph Barberá.

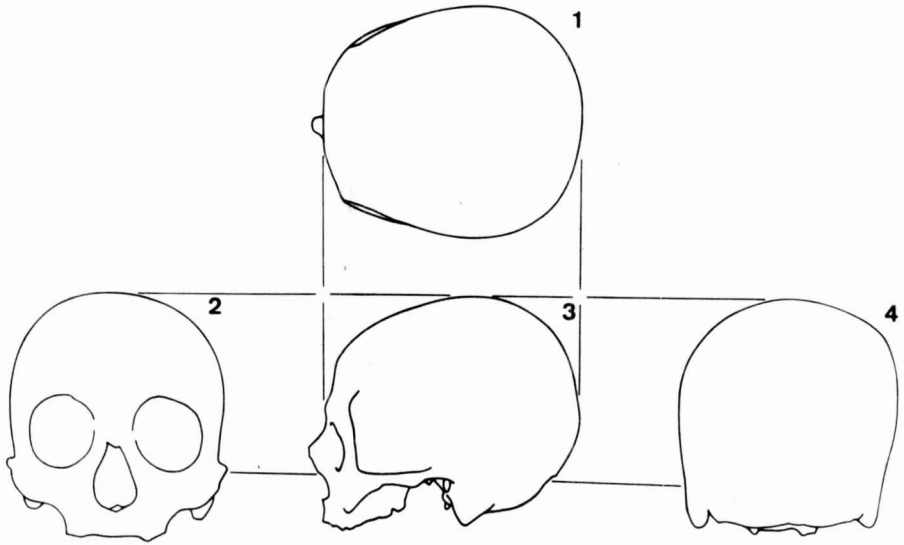


Fig. 1.—Craneogrammes: 1, superior view; 2, anterior view; 3, lateral view; 4 posterior view.

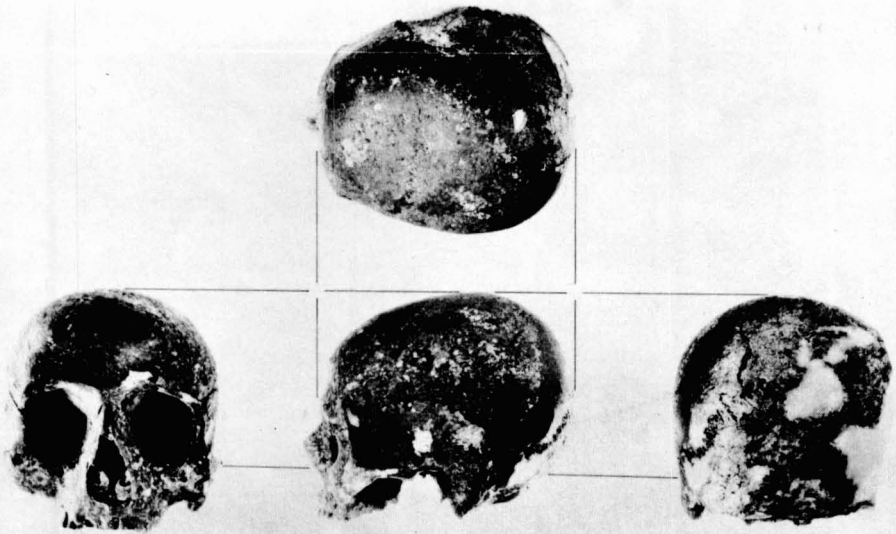


Fig. 2.—Photographs of the cranium according to its different view.

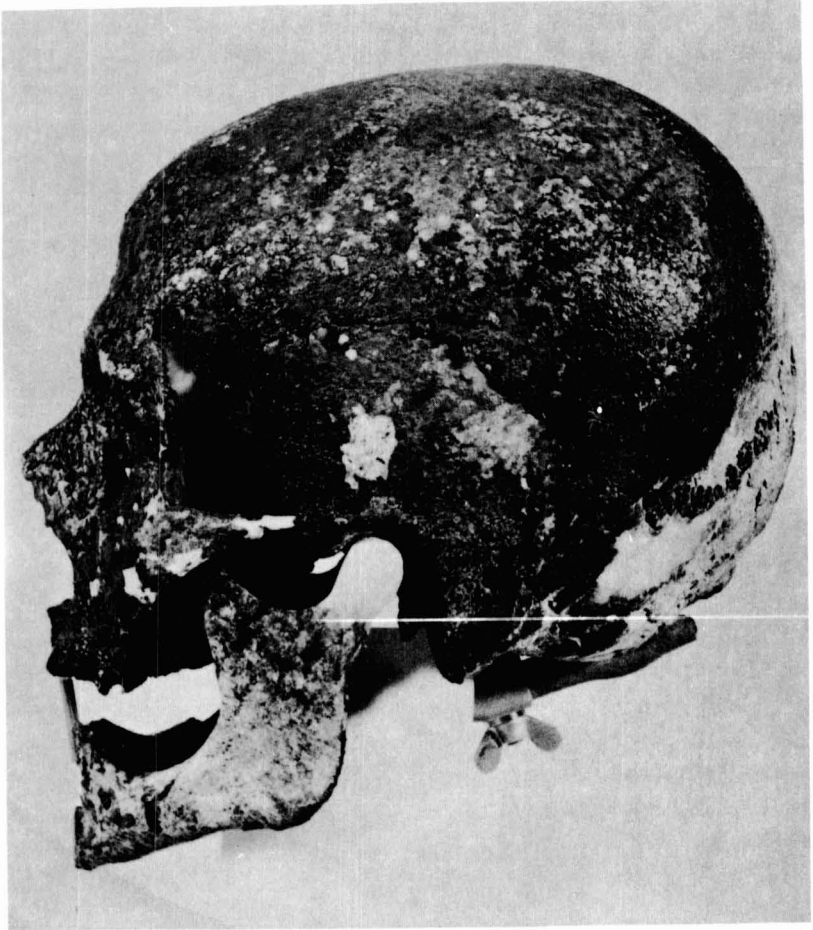


Fig. 3.—Cranium with its mandibule, seen from the left lateral view.

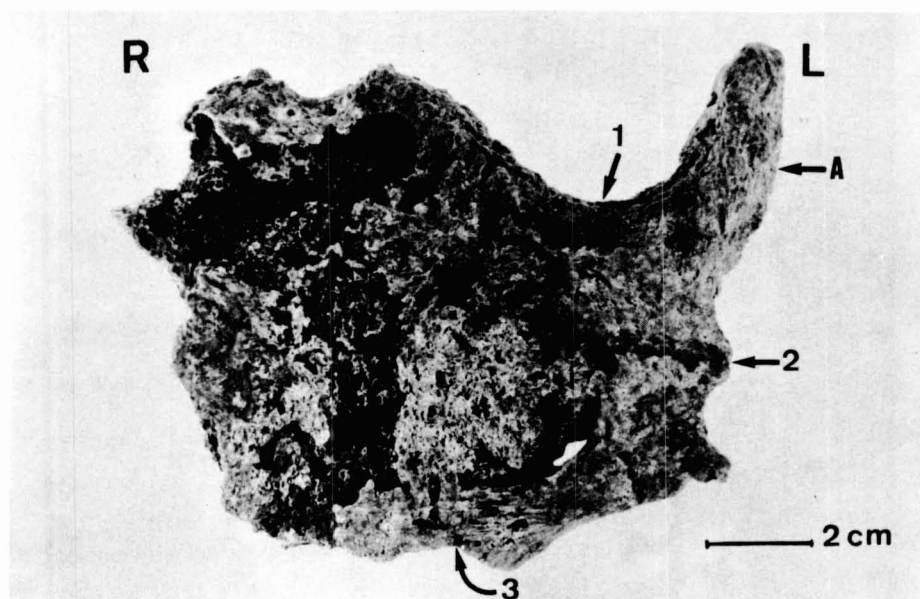


Fig. 4.—Manubrium of the sternum. R, right; L, left. A, anomalous apophysis with Srb's malformation. 1, line along which the left external margin of the sternum would be approximately situated; 2, junction point which would correspond to the midline between the first and second ribs; 3, ossified fascicle of union between the second rib and the body of the sternum.



Fig. 5.—Bust seen from the front in which one can appreciate the deterioration of the right supraciliary arch, of the head of the left eyebrow and the nose.




Fig. 6.—Bust seen from the side, in which the deterioration of the glabella is highly evident, as well as the lack of the nose and of the occipital region.

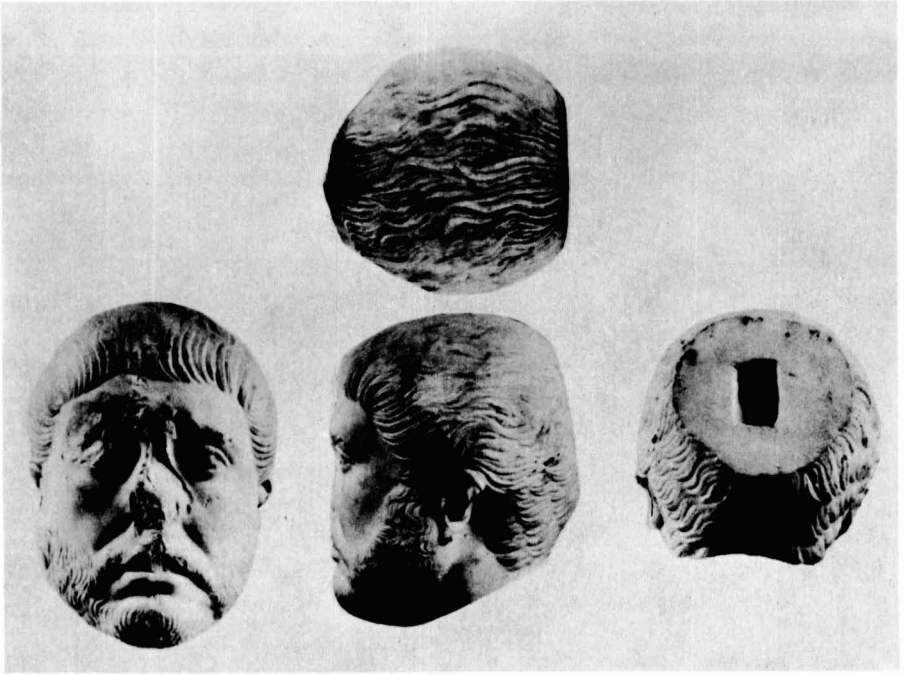


Fig. 7.—Cranium seen in its different views. See how a fragments of marble is missing from the occipital region.

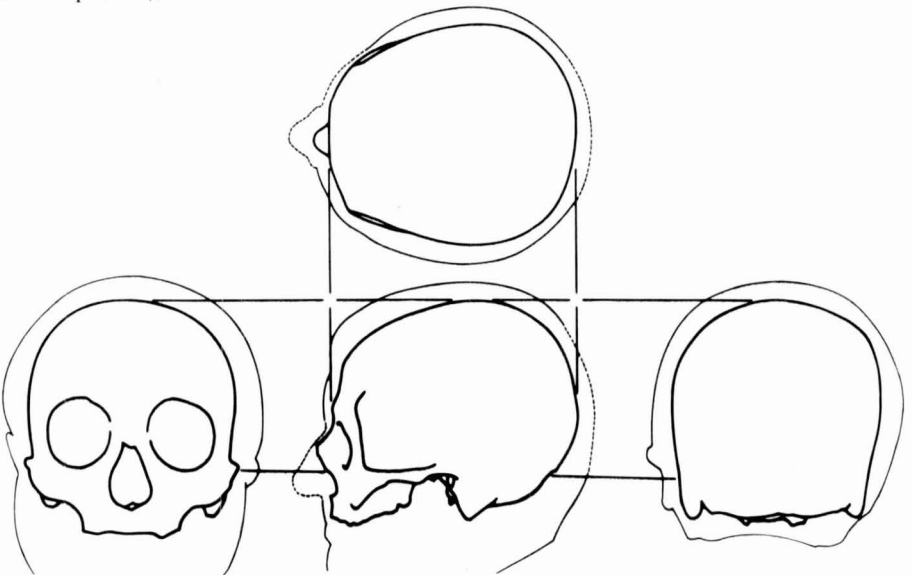


Fig. 8.—Cranecogrammes to which the silhouettes of the bust have been superimposed.

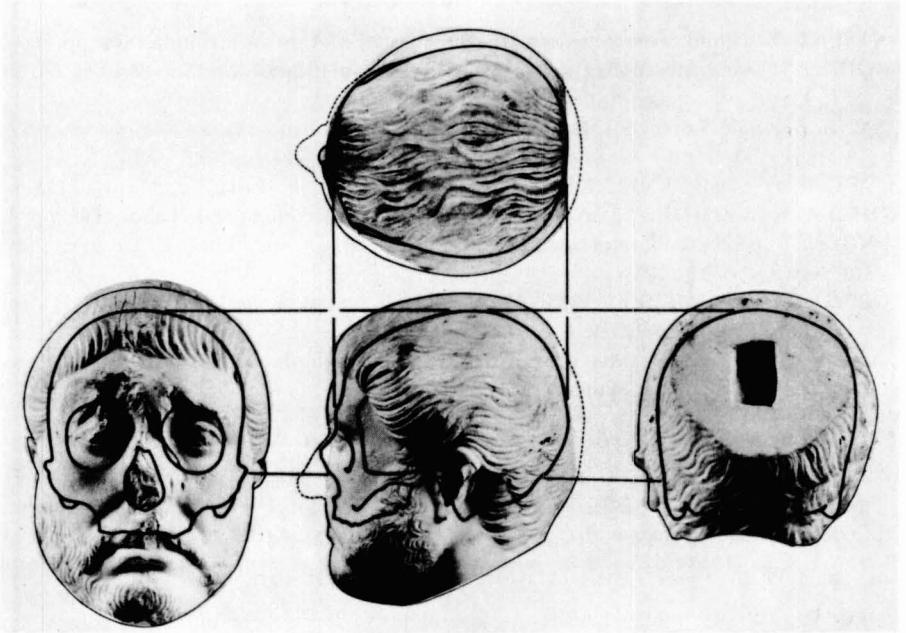


Fig. 9.—Photographs of the bust to which the craniogrammes have been superimposed taking into account the probable thickness of the hair and of the epicranial tissues. The dotted line shows the zones of the bust which have been lost due to deterioration.

BIBLIOGRAPHY

- BARTUCZ, L. (1966). *Palaeopathologia III*. Budapest, Ed. Franklin-nyomda, 612 pp.
- BROCA, P. (1785). Instructions craniologiques et craniométriques. *Mém. Soc. d'Anthrop. de Paris*, 63, 1- 103.
- GENNA, G. (1958). Lorenzo il Magnifico e il suo fratello Giuliano. «Estrato dai Rendiconti dell'Accademia Nazionale dei XL (80.º dalla fondazione)». Seri IV(VIII): 1-95 + XLV T.
- JUDET, R. et LETOURNEL, E. (1974): *Les fractures du cotyle*. Paris, Ed, Masson, 178 pp.
- KÖHLER, A. y ZIMMER, E. A. (1959): *Roentgenologia*. Barcelona, Ed. Labor, 708 pp.
- LENGYEL, I. (1976). Laboratory examination of skeletal remains from J. C. Lavater's grave. *Gesnerus*, 33:381- 384.
- LÓPEZ-PIÑERO, J. M. (Dir.) (1988): *Historia de la Medicina Valenciana, I*. Valencia, Ed. Vicent García, 162 pp.
- LÓPEZ TERRADA, M. L. (1988): La medicina en la Valencia romana. En *Hist. Med. Valenciana*, dir. por J. M. López- Piñero. I: 59-61.
- MANDUVRIER, L. (1893): La détermination de la taille d'après les grands membres. *Mem. Soc. d'Anthrop. de Paris*, 4:347-402.
- MARTIN, R. und SALLER, K. (1957): *Lehrbuch der Anthropologie, III*. Stuttgart, Ed. Gustav Fischer, 634 pp.
- OLIVIER, G. (1960): *Pratique Anthropologique*. Paris, Ed. Vigot, 299 pp.
- PIULACHS, P. (1958): *Lecciones de patología quirúrgica, II (1.ª part.)*. Barcelona, Ed. Toray, 935 pp.
- SCHMORL, G. (1932): Über Verlagerung von Bandscheibengewebe und ihre Folgen. *Arch. Klin. Chir.*, 172:34-72
- SCHULTZ, A. H. (1949): Sex differences in the pelvis of primates. *Am. J. of Phys. Anthrop.*, Z:401-423.
- SRB, (1962): *Med. Jb. K.K. Ges. d. Aerzte-Viena*.
- STEWART, T. D. (1958): Therate of development of vertebral osteo-arthritis in America Whites and its significance in skeletal age identification. Johannesburg, *The Leech*, 28:144-151.
- TARRACO, *Objecte i Imatge*. Tarragona, Ed. Generalitat de Catalunya i Diputació de Tarragona, 144 pp.
- TROTTER, M. and GLESER, G. C. (1958): A re-evaluation of estimation of stature based on measurements of stature taken during life and of long bones after death. *Am. J. of Phys. Anthrop.*, 16:79-124.
- VILLIERS, H. (1968): *The Skull of the South African Negro*. Johannesburg, Ed. Witwatersrand Univ. Press., 159.