

Positive response to clozapine augmentation in a patient with obsessive-compulsive disorder complicated by a tardive movement disorder

Rev Bras Psiquiatr. 2018;40:229–230
Brazilian Journal of Psychiatry
CC-BY-NC | doi:10.1590/1516-4446-2017-2565

The pharmacological treatment of obsessive-compulsive disorder (OCD) and obsessive-compulsive symptoms (OCS) can be a clinical challenge. The prevalence of OCD in the general population is 1-2%, but the prevalence of OCS is 12% in schizophrenia¹ and 16% in bipolar disorder.²

Antipsychotic agents are used for augmentation in severe OCD. Conversely, in schizophrenia, clozapine and, to a lesser extent, olanzapine and risperidone have been associated with worsening or *de novo* development of OCS.^{2,3}

We report the case of a patient with primary OCD who developed a tardive movement disorder that responded to clozapine augmentation.

A 35-year-old Venezuelan woman of African descent consulted the first author for severe obsessions about her skills as a dentist and for repetitively checking her procedures in front of her clients. These symptoms had lasted 2 months. She had previously experienced a severe episode of OCD at the age of 14, which improved spontaneously but left mild residual symptoms, such as compulsory cleaning and ordering. She described a lack of response to trials of quetiapine, lamotrigine, and transcranial magnetic stimulation. Fluoxetine (20 mg/day), risperidone (1 mg/day), and clonazepam (1 mg/day) were started, with an excellent response after 1 week of treatment.

After 3 months, she returned due to dyskinetic movements of her lips and jaws and focal dystonia of the tongue, which were diagnosed as tardive dyskinesia and dystonia by a consulting neurologist. Risperidone was discontinued; biperiden (8 mg/day) was partially effective for the abnormal movements for 2 months, at which time OCS recurred, along with severe anxiety associated with the abnormal mouth movements, which forced her to stop working. At that time, she was taking fluoxetine 40 mg/day and clonazepam 1 mg/day. Biperiden was discontinued and clozapine augmentation was added at bedtime, starting at 25 mg and escalating to 50 mg after 10 days. The OCS, abnormal movements, and anxiety improved considerably, and she was able to resume work 1 month after starting clozapine augmentation. The only remaining OCS after clozapine augmentation was described by the patient as a “tormenting thought” in the early morning, which was managed with cognitive psychotherapy and

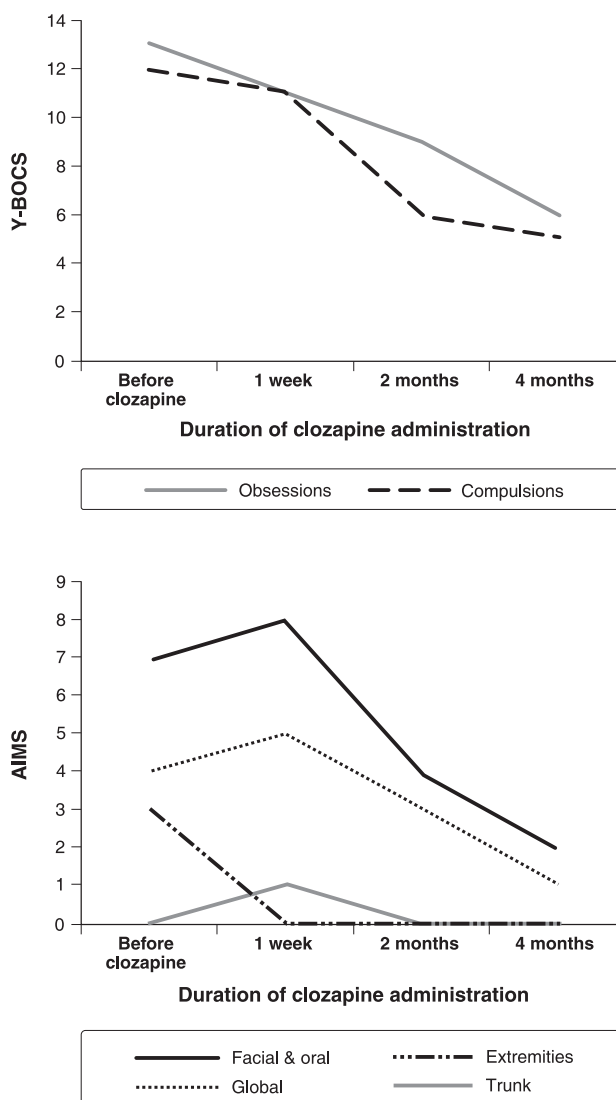


Figure 1 Yale-Brown Obsessive-Compulsive Scale (Y-BOCS) and Abnormal Involuntary Movement Scale (AIMS) scores during clozapine administration.

neurofeedback. Figure 1 shows the course of her Abnormal Involuntary Movement Scale (AIMS) and Yale-Brown Obsessive-Compulsive Scale (Y-BOCS) scores during clozapine administration.

This report describes a patient with severe, primary, non-psychotic OCD who, after starting low-dose risperidone to augment fluoxetine, unfortunately developed a tardive movement disorder (dyskinesia/dystonia). Fluoxetine is a CYP2D6 and CYP3A4 inhibitor, and inhibits risperidone metabolism. After stopping risperidone, augmentation of fluoxetine and clonazepam with a low dose of clozapine (50 mg/day) led to improvement in OCS and abnormal movements. Fluoxetine is a mild inhibitor of clozapine metabolism, but in typical patients, this effect is small (equivalent to multiplying the clozapine dose by 1.3).⁴

The literature supports the use of clozapine for tardive dyskinesia.⁵ While there is a concern about using clozapine in patients with psychosis and OCS,^{1,3} this report further contributes to the literature supporting the use of short-term

clozapine augmentation for cases of complicated primary OCD.

Trino Baptista,¹ José de Leon^{2,3,4}

¹*Departamento de Fisiología, Facultad de Medicina, Universidad de los Andes, Mérida, Venezuela.* ²*Mental Health Research Center, Eastern State Hospital, Lexington, KY, USA.* ³*Grupo de Investigación en Psiquiatría y Neurociencias (CTS-549), Instituto de Neurociencias, Universidad de Granada, Granada, España.* ⁴*Centro de Investigación Biomédica en la Red de Salud Mental (CIBERSAM), Hospital Santiago Apostol, Universidad del País Vasco, Vitoria, España*

Submitted Dec 03 2017, accepted Dec 22 2017.

Acknowledgments

The authors acknowledge Lorraine Maw, M.A., at the Mental Health Research Center at Eastern State Hospital, Lexington, KY, USA, and Françoise Meyers, at Facultad de Medicina, Universidad de los Andes, Mérida, Venezuela, for their help in editing this manuscript.

Disclosure

The authors report no conflicts of interest.

References

- 1 Schirmbeck F, Zink M. Comorbid obsessive-compulsive symptoms in schizophrenia: contributions of pharmacological and genetic factors. *Front Pharmacol.* 2013;4:99.
- 2 Jeon S, Baek JH, Yang SY, Choi Y, Ahn SW, Ha K, et al. Exploration of comorbid obsessive-compulsive disorder in patients with bipolar disorder: the clinic-based prevalence rate, symptoms nature and clinical correlates. *J Affect Disord.* 2017;225:227-33.
- 3 Leung JG, Palmer BA. Psychosis or obsessions? Clozapine associated with worsening obsessive-compulsive symptoms. *Case Rep Psychiatry.* 2016;2016:2180748.
- 4 Spina E, de Leon J. Clinically relevant interactions between newer antidepressants and second-generation antipsychotics. *Expert Opin Drug Metab Toxicol.* 2014;10:721-46.
- 5 Grover S, Hazari N, Kate N, Chakraborty K, Sharma A, Singh D, et al. Management of tardive syndromes with clozapine: a case series. *Asian J Psychiatr.* 2014;8:111-4.