



# Sauvé-Kapandji and reverse Sauvé-Kapandji procedures for treating chronic longitudinal radioulnar dissociation with capitellum fracture

Pedro HERNÁNDEZ-CORTÉS<sup>1</sup>, Rafael GÓMEZ-SÁNCHEZ<sup>1</sup>,  
Miguel PAJARES-LÓPEZ<sup>1</sup>, Francisco O'VALLE-RAVASSA<sup>2</sup>

<sup>1</sup>University San Cecilio Hospital of Granada, Department of Orthopedics and Traumatology, Granada, Spain;

<sup>2</sup>University of Granada, Faculty of Medicine, Department of Pathology, Granada, Spain

Almost all reported cases of longitudinal radioulnar dissociation have involved fracture of the radial head, rupture of the interosseous membrane, and disruption of the distal radioulnar joint, although unusual patterns of Essex-Lopresti injury have also been described. To our knowledge, this is the first report of a chronic Essex-Lopresti variant including fracture of the capitellum. A displaced capitellum fracture must alert to the possibility of longitudinal radioulnar dissociation, even without concomitant radial head fracture or symptoms at the forearm and ulnar wrist. Successful mid-term results can be achieved by treating malunion of humeral condyle and proximal migration of the radius with simultaneous Sauvé-Kapandji procedure at the wrist and reverse Sauvé-Kapandji at the elbow.

**Key words:** Sauvé-Kapandji procedure; longitudinal radioulnar dissociation.

In 1951, Peter Essex-Lopresti described a type of longitudinal radioulnar dissociation that now bears his name.

<sup>[1]</sup> The injury results from axial forces to the forearm, usually a high energy fall onto an outstretched hand, which disrupts the radial head, interosseous membrane (IOM), and distal radioulnar joint (DRUJ), leading to axial instability.<sup>[2]</sup>

Essex-Lopresti injury is often missed during initial assessment, but early recognition of longitudinal forearm instability is critically important because the management of chronic cases, in which longitudinal radioulnar dissociation is diagnosed after radial migration, is complex and no clear solution exists.<sup>[2]</sup>

Primary restraint against proximal migration of the

radius is abutment of the capitellum. Soft-tissue structures that provide additional forearm longitudinal stability are considered secondary restraints and include the interosseous membrane of the forearm, the triangular fibrocartilage, and the ligaments of the distal radioulnar joint.<sup>[3]</sup>

The goal of the present case report was to describe an atypical variant of Essex-Lopresti injury and propose a new treatment for chronic longitudinal radioulnar dissociation with capitellum fracture.

## Case report

A 32-year-old right-hand dominant male with no prior medical history was referred to our Department in

**Correspondence:** Miguel Pajares-López, MD. Departamento de Ortopedia-Traumatología, del Hospital Universitario San Cecilio, Av. Dr. Olóriz 16, 18012-Granada, Espana.

Tel: (+34) 958 023 077 e-mail: mpajareslopez@hotmail.com

**Submitted:** November 21, 2012 **Accepted:** March 16, 2013

©2014 Turkish Association of Orthopaedics and Traumatology

Available online at  
www.aott.org.tr

doi: 10.3944/AOTT.2014.3121

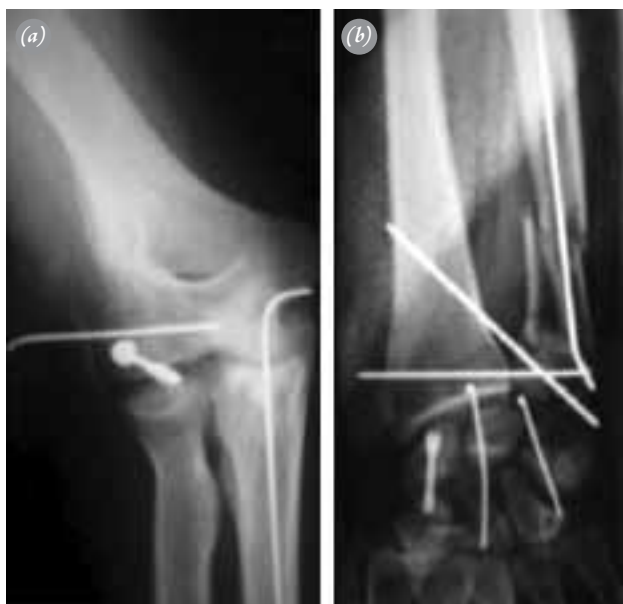QR (Quick Response) Code



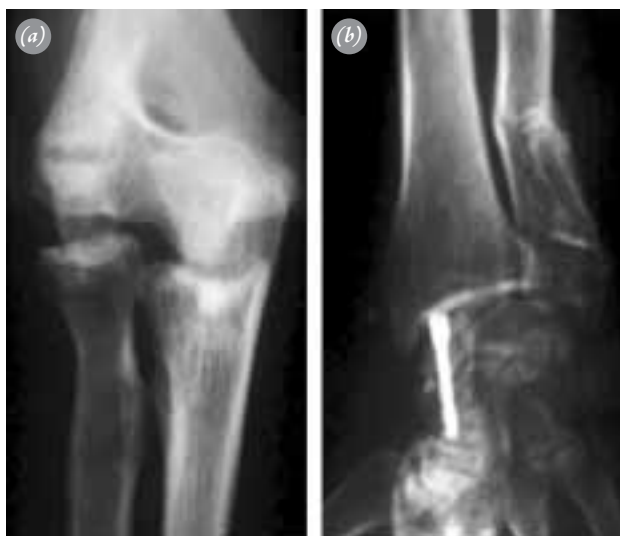
March 2009 at eight weeks after a fall from a church roof that caused fractures of the humeral condyle and distal ulna and dorsal transscaphoid perilunate fracture-dislocation in his left upper limb. Osteosynthesis with screw and Kirschner wire and pinning between the radius and ulna were performed at the Regional Hospital on the day of the accident (Fig. 1 a and b).

We removed the hardware from the elbow, ulna, and wrist, leaving the scaphoid Herbert screw because the scaphoid fracture was not healed. The patient was then referred to the Rehabilitation Department for functional recovery. Three months later, he visited us to report pain and disability in the left elbow and the ulnar side of the wrist.

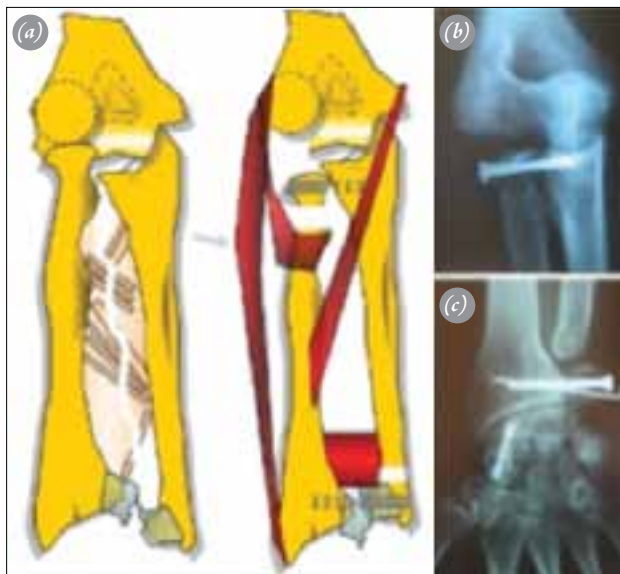
A new radiographic study showed deformity of the humeral condyle and proximal migration of the radius, with proximal and distal radioulnar dislocation at the affected forearm (Fig. 2 a and b). A CT-scan confirmed these findings, but no useful additional information could be obtained without 3D reconstruction. A chronic disruption of IOM and atypical longitudinal radioulnar dissociation was suspected. The patient had a 45° loss of elbow extension, a maximal flexion of 95°, and global pronation-supination range of motion of 60°.



**Fig. 1.** Radiographic study of left elbow and wrist at 6 weeks after the accident at the first consultation in our center. **(a)** Humeral condyle fracture was treated by unorthodox internal fixation using spongy screw of 4.0 mm and Kirschner wire. **(b)** Wrist radiography, showing fracture-dislocation of distal ulna treated with intramedullar Kirschner wire osteosynthesis and distal radioulnar joint transfixion, and Kirschner wire and Herbert screw fixation of transscaphoid-perilunate dislocation of the carpus.

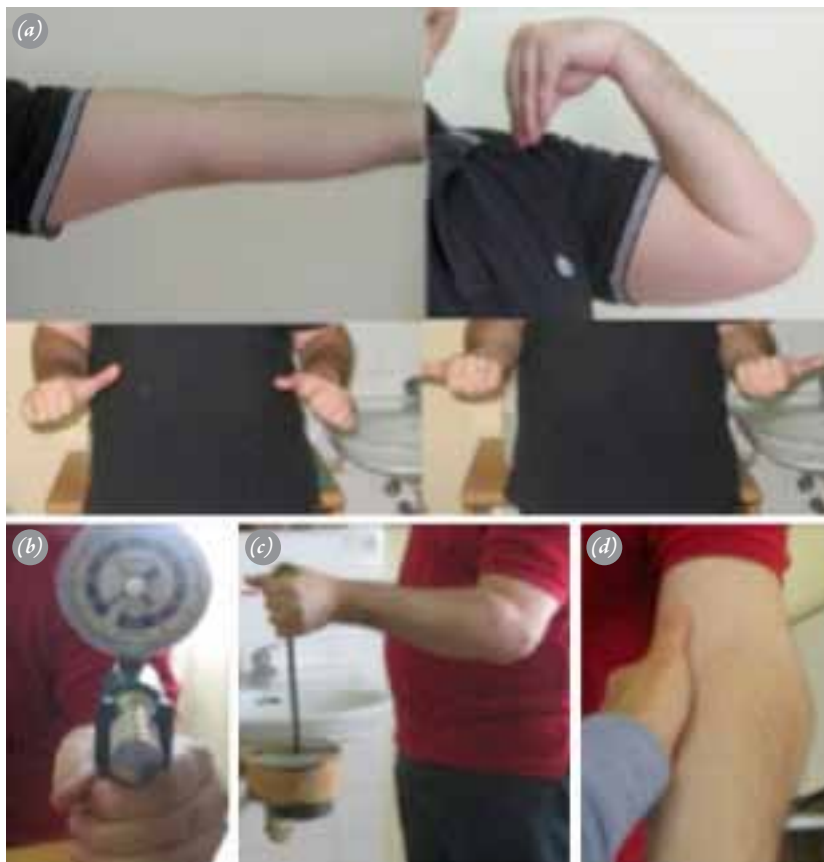

**Fig. 2.** Radiographic changes after removal of hardware. **(a)** Condylar deformity and proximal migration of the radius with proximal radioulnar dislocation. **(b)** Malaligned consolidation of the ulna and radioulnar discrepancy due to radius ascension.



**Fig. 3.** Surgical treatment. **(a)** Schematic drawing of the lesion (left) and planning of the Sauvé-Kapandji procedure at the wrist and elbow. **(b)** Two-year radiographic follow-up of reverse Sauvé-Kapandji procedure. Although no true bone union is achieved, the radial head and lesser sigmoid notch relationship remains stable. **(c)** Two-year radiographic follow-up of Sauvé-Kapandji procedure at left wrist. [Color figure can be viewed in the online issue, which is available at [www.aott.org.tr](http://www.aott.org.tr)]

The patient accepted a new surgical reconstruction. The operation consisted of a Sauvé-Kapandji procedure at the wrist and reverse Sauvé-Kapandji at the elbow (Fig. 3 a, b and c). Distal translation of the radial head for arthrodesis to the lesser sigmoid notch of the ulna released the abutment to the capitellum and freed the



**Fig. 4.** Two years follow-up functional outcome. **(a)** Range of motion: the patient reached complete extension and 120° of elbow flexion. The pronation-supination arc was close to normal. **(b)** Grip strength of the affected hand reached 35 kg. **(c)** The patient was able to lift 12 kg. **(d)** An asymptomatic moderate varus laxity was detected. [Color figure can be viewed in the online issue, which is available at [www.aott.org.tr](http://www.aott.org.tr)]

flexo-extension elbow movement. Intentional pseudoarthroses at the neck of the radius and distal ulna allowed recovery of the pronation to supination arc.

After six weeks of rehabilitation, the patient reached his current functional status at two years after operation, with no pain at rest or during moderate physical activities and a near-normal range of motion of the elbow and forearm rotation (Fig. 4a). Grip strength measured with a Jamar dynamometer was 35 kg for the left non-dominant affected upper limb and 51 kg for the right hand (Fig. 4b). The patient was able to lift 12 kg (Fig. 4c) and felt the elbow as a stable joint, although modest laxity with varus stress was revealed (Fig. 4d). No clinical deterioration has been observed during his follow-up.

## Discussion

Almost all reported longitudinal radioulnar dissociations have consisted of a fracture of the radial head, rupture of the interosseous membrane and disruption of the distal radioulnar joint.<sup>[4,5]</sup> However, unusual patterns of

Essex-Lopresti injury have been described, including: dislocation of both radial head and distal radioulnar joint without fracture, combined Essex-Lopresti and radial shaft fracture, IOM injury associated with complex radial head and ulnar shaft fractures, longitudinal forearm dissociation in which the DRUJ injury consisted of an ulnar head fracture, and Essex-Lopresti injury with a radial neck fracture.<sup>[4,6-10]</sup>

To our knowledge, this is the first report of an Essex-Lopresti variant with fracture of the capitellum. The pathoanatomy and biomechanics of this lesion are equivalent to those of the classic type of longitudinal radioulnar dissociation. Although Sabo et al. found no appreciable change in proximal radioulnar kinematics after excision of the entire capitellum in a cadaveric model, they did not evaluate the effect of simultaneous IOM damage.<sup>[11]</sup>

Transfixation of the distal radioulnar joint initially prevented radius displacement in our patient but, as reported in other cases, the IOM failed to heal despite

internal fixation of the ulna, cross-pinning of the distal radioulnar joint and arm cast immobilization for six weeks.<sup>[7]</sup> Proximal displacement of the radius developed after extraction of the wires and led to proximal and distal radioulnar dislocation, with elbow pain and limitation of elbow and wrist motion and forearm rotation.

There are no reliable reconstructive surgical techniques to restore forearm stability in patients with chronic radioulnar dissociation, with only a few limited series described in the English-language literature.<sup>[1,4,5,12-14]</sup> Treatment goals in these cases ideally include normalization of the radioulnar relationship at the distal radioulnar joint and prevention of further migration of the radius.<sup>[3]</sup> Surgical options included restoration of the radiocapitellar joint, length-equalizing procedures, IOM reconstruction, or radioulnar arthrodesis, or a combination of these.

Given that fracture of the radial head is the usual bone lesion in chronic Essex-Lopresti injuries, attempts to reconstruct the radiocapitellar joint with implantation of a frozen-allograft radial head or metallic radial head have been reported.<sup>[13-15]</sup> However, these treatment options were not suitable in our patient because there was no injury of the radial head. We did not consider to perform an intraarticular osteotomy of the humeral condyle malunion to restore radiocapitellar joint, because the risk of avascular necrosis of the capitellum.

Although procedures such as distal ulnar resection, the Sauvé-Kapandji procedure, and segmental shortening of the ulna can reestablish normal ulnar variance in the early postoperative setting, they do not restore the soft-tissue stabilizers of the forearm, and patients usually experience continued proximal radial migration.<sup>[5,10,16]</sup>

Multiple techniques have been described using various tissues for reconstruction of the IOM, including bone-patellar tendon-bone autograft in chronic longitudinal radioulnar instability.<sup>[17-19]</sup> Finally, the creation of a one-bone forearm, or radioulnar synostosis, has been advocated as a salvage procedure.<sup>[20]</sup>

We thought that radioulnar arthrodesis was the best way to restore a normal radioulnar relationship. Distal translation of the radial head for alignment to the lesser sigmoid notch of the ulna for fusion allows release of the radiocapitellar joint and restores elbow flexo-extension movement. The main challenge was to fix the forearm in a permanent rotational position, but this was overcome by combining a Sauvé-Kapandji operation at the wrist with a reverse procedure at the elbow. A similar technique has been successfully applied to treat proximal ra-

dioulnar synostosis.<sup>[21]</sup> Our proposed technique yielded an excellent outcome at two-years post-surgery.

Nevertheless, increased joint contact forces can be expected at the remaining ulnohumeral articulation due to the reduction in articular surface area and the redistribution of load from the lateral column of the elbow, increasing the risk of ulnohumeral osteoarthritis.<sup>[22]</sup>

In conclusion, a displaced capitellum fracture must alert to possible longitudinal radioulnar dissociation, even without concomitant radial head fracture or symptoms at the forearm and ulnar wrist. Successful mid-term results can be achieved by treating malunion of the humeral condyle and proximal migration of the radius with simultaneous Sauvé-Kapandji procedure at the wrist and reverse Sauvé-Kapandji at the elbow.

**Conflicts of Interest:** No conflicts declared.

## References

1. Essex-Lopresti P. Fractures of the radial head with distal radio-ulnar dislocation; report of two cases. *J Bone Joint Surg Br* 1951;33B:244-7.
2. Dodds SD, Yeh PC, Slade JF 3rd. Essex-lopresti injuries. *Hand Clin* 2008;24:125-37. [CrossRef](#)
3. Rozental TD, Beredjikian PK, Bozentka DJ. Longitudinal radioulnar dissociation. *J Am Acad Orthop Surg* 2003;11:68-73.
4. Edwards GS Jr, Jupiter JB. Radial head fractures with acute distal radioulnar dislocation. Essex-Lopresti revisited. *Clin Orthop Relat Res* 1988;234:61-9.
5. Trousdale RT, Amadio PC, Cooney WP, Morrey BF. Radio-ulnar dissociation. A review of twenty cases. *J Bone Joint Surg Am* 1992;74:1486-97.
6. Eglseder WA, Hay M. Combined Essex-Lopresti and radial shaft fractures: case report. *J Trauma* 1993;34:310-2.
7. Gong HS, Chung MS, Oh JH, Lee YH, Kim SH, Baek GH. Failure of the interosseous membrane to heal with immobilization, pinning of the distal radioulnar joint, and bipolar radial head replacement in a case of Essex-Lopresti injury: case report. *J Hand Surg Am* 2010;35:976-80. [CrossRef](#)
8. Auyeung J, Broome G. The Essex-Lopresti lesion: a variant with a bony distal radioulnar joint injury. *J Hand Surg Br* 2006;31:206-7. [CrossRef](#)
9. Rodriguez-Martin J, Pretell-Mazzini J, Vidal-Bujanda C. Unusual pattern of Essex-Lopresti injury with negative plain radiographs of the wrist: a case report and literature review. *Hand Surg* 2010;15:41-5. [CrossRef](#)
10. Duckworth AD, Clement ND, Aitken SA, Ring D, McQueen MM. Essex-Lopresti lesion associated with an impacted radial neck fracture: interest of ulnar shortening in the secondary management of sequelae. *J Shoulder Elbow Surg* 2011;20:19-24. [CrossRef](#)

11. Sabo MT, Fay K, McDonald CP, Ferreira LM, Johnson JA, King GJ. Effect of coronal shear fractures of the distal humerus on elbow kinematics and stability. *J Shoulder Elbow Surg* 2010;19:670-80. [CrossRef](#)
12. Jungbluth P, Frangen TM, Arens S, Muhr G, Källicke T. The undiagnosed Essex-Lopresti injury. *J Bone Joint Surg Br* 2006;88:1629-33. [CrossRef](#)
13. Karlstad R, Morrey BF, Cooney WP. Failure of fresh-frozen radial head allografts in the treatment of Essex-Lopresti injury. A report of four cases. *J Bone Joint Surg Am* 2005;87:1828-33. [CrossRef](#)
14. Szabo RM, Hotchkiss RN, Slater RR Jr. The use of frozen-allograft radial head replacement for treatment of established symptomatic proximal translation of the radius: preliminary experience in five cases. *J Hand Surg Am* 1997;22:269-78. [CrossRef](#)
15. Heijink A, Morrey BF, van Riet RP, O'Driscoll SW, Cooney WP 3rd. Delayed treatment of elbow pain and dysfunction following Essex-Lopresti injury with metallic radial head replacement: a case series. *J Shoulder Elbow Surg* 2010;19:929-36. [CrossRef](#)
16. Sowa DT, Hotchkiss RN, Weiland AJ. Symptomatic proximal translation of the radius following radial head resection. *Clin Orthop Relat Res* 1995;317:106-13.
17. Marcotte AL, Osterman AL. Longitudinal radioulnar dissociation: identification and treatment of acute and chronic injuries. *Hand Clin* 2007;23:195-208. [CrossRef](#)
18. Adams JE, Steinmann SP, Osterman AL. Management of injuries to the interosseous membrane. *Hand Clin* 2010;26:543-8. [CrossRef](#)
19. Adams JE, Culp RW, Osterman AL. Interosseous membrane reconstruction for the Essex-Lopresti injury. *J Hand Surg Am* 2010;35:129-36. [CrossRef](#)
20. Peterson CA 2nd, Maki S, Wood MB. Clinical results of the one-bone forearm. *J Hand Surg Am* 1995;20:609-18.
21. Kamineni S, Maritz NG, Morrey BF. Proximal radial resection for posttraumatic radioulnar synostosis: a new technique to improve forearm rotation. *J Bone Joint Surg Am* 2002;84-A:745-51.
22. Ikeda M, Oka Y. Function after early radial head resection for fracture: a retrospective evaluation of 15 patients followed for 3-18 years. *Acta Orthop Scand* 2000;71:191-4.