



# Psychosis and Dandy-Walker syndrome: a case report and review of the literature

Alejandro Porras Segovia,<sup>1</sup> Margarita Guerrero-Jiménez ,<sup>2</sup>  
Carmen Maura Carrillo de Albornoz Calahorro,<sup>2</sup> Luis Gutierrez-Rojas <sup>3</sup>

**To cite:** Porras Segovia A, Guerrero-Jiménez M, Carrillo de Albornoz Calahorro CM, *et al.* Psychosis and Dandy-Walker syndrome: a case report and review of the literature. *General Psychiatry* 2021;**34**:e100254. doi:10.1136/gpsych-2020-100254

Received 09 May 2020  
Revised 21 February 2021  
Accepted 02 March 2021

## ABSTRACT

Dandy-Walker syndrome (DWS) is a group of brain malformations which sometimes present with psychotic symptoms. We present the case of a patient diagnosed with Dandy-Walker variant who presented with schizophrenia-like psychosis. A man in his 30s was admitted to an acute psychiatric unit presenting with persecutory delusions, auditory hallucinations and violent behaviour. The MRI performed showed the typical alterations of Dandy-Walker variant: vermian hypoplasia and cystic dilatation of the fourth ventricle. He also suffered from mild intellectual disability. After being treated with olanzapine 10 mg/d for a month, his psychotic symptoms greatly improved and he was discharged. In conclusion, DWS may cause psychosis through a dysfunction in the circuit connecting prefrontal, thalamic and cerebellar areas. The association between these two conditions may contribute to the understanding of the aetiopathogenesis of schizophrenia.

## INTRODUCTION

Dandy-Walker syndrome (DWS) is a group of brain structural abnormalities that includes four subtypes: Dandy-Walker malformation, mega cisterna magna, posterior fossa arachnoid cyst and Dandy-Walker variant.<sup>1</sup>

Dandy-Walker variant is the mildest form and is characterised by vermian hypoplasia and cystic dilatation of the fourth ventricle. Its clinical presentation typically consists of intellectual disability and epileptic seizures, although some patients may remain asymptomatic. Diagnosis is based on neuroimaging tests, mainly MRI. There is currently no curative treatment and, consequently, therapeutic strategies focus on its symptoms and complications.<sup>2</sup>

Occasionally, psychotic symptoms and other psychiatric disorders have been reported to occur in patients with DWS.<sup>3–18</sup> However, the prevalence and clinical features of this comorbidity have not been established yet, and the literature about the topic is scarce. This is not the only neurological condition that presents with psychiatric comorbidities: several brain alterations, both structural and pathophysiological, can result in psychiatric

symptoms.<sup>19</sup> Moreover, neurodevelopmental factors have been found to be involved in the aetiology of schizophrenia,<sup>20–22</sup> and the cerebellum appears to play an important role in this process.<sup>23–26</sup>

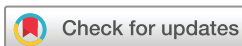Here we present the case of a patient diagnosed with Dandy-Walker variant who presented with schizophrenia-like psychosis. The identification and description of such cases is of clinical relevance, since Schizophrenia-like symptoms induced by neurological conditions may present clinical features that differentiate them from primary schizophrenia, which may result in the need for different treatment approaches. Further on we present a narrative review of the association between psychosis and DWS, which, to our knowledge, is the first review conducted on the topic.

## CASE PRESENTATION

A man in his 30s was admitted to an acute psychiatric unit after presenting with delusions and violent behaviour.

The patient had been diagnosed with Dandy-Walker variant as a child, manifesting as mild cognitive impairment and epileptic seizures. Electroencephalogram had revealed the presence of a rolandic focus, and MRI studies had shown vermian hypoplasia and dilatation of the fourth ventricle. He was treated with valproate for several years until seizures stopped around the age of 15 years. He lived with his mother, had no friends and worked as a janitor in a primary school.

A year prior to his admission, he started to feel suspicious of his neighbours and thought the children in the school where he worked made fun of him. He occasionally manifested aggressive behaviour, insulting and threatening his neighbours. The day before his admission, at the age of 32, the patient stepped into a school class wielding a knife and threatened the children and their teacher. He was arrested but was declared legally unaccountable after forensic psychiatric evaluation.



© Author(s) (or their employer(s)) 2021. Re-use permitted under CC BY-NC. No commercial re-use. See rights and permissions. Published by BMJ.

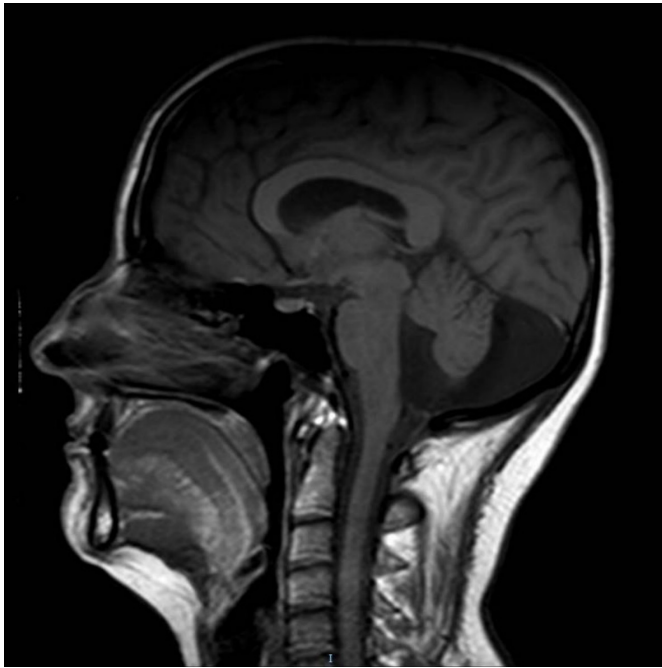
<sup>1</sup>Department of Psychiatry, Hospital Universitario Fundación Jiménez Díaz, Madrid, Madrid, Spain

<sup>2</sup>Department of Psychiatry, Hospital Universitario Virgen de las Nieves, Granada, Andalucía, Spain

<sup>3</sup>Department of Psychiatry, University of Granada, Granada, Andalucía, Spain

## Correspondence to

Dr Margarita Guerrero-Jiménez; marlliguerrero@gmail.com



**Figure 1** Midsagittal magnetic resonance T1-weighted scan shows cystic dilatation of the fourth ventricle and vermian hypoplasia.

He was transferred to the emergency room and later admitted to a psychiatric emergency ward.

At admission, the patient presented with persecutory delusions, claiming that the schoolchildren and other townspeople were planning to end his life and defended his actions as self-defence. He also presented with auditory hallucinations, claiming he could hear the voices from the deceased with whom he talked daily. He did not display thought disorder, but some limitations in abstract thinking and a mild intellectual disability (Wechsler Adult Intelligence Scale III score of 65) were evident on examination.

The patient gave written informed consent to all diagnostic procedures and allowed us to use the available data for scientific reports. An MRI was performed, showing the typical alterations of Dandy-Walker variant. No other alterations were found ([figure 1](#)).

He was treated with olanzapine 10 mg/d. Apart from mild sedation, which decreased after the first week, he tolerated the medication. His psychotic symptoms greatly improved a month after admission, with full remission of auditory hallucinations and a reduction from 87 to 51 in the Positive and Negative Syndrome Scale (PANSS). His delusions persisted but greatly decreased in intensity. He was discharged from the hospital and his care was transferred to his local mental health outpatient team.

## DISCUSSION

This case illustrates the association between Dandy-Walker variant and schizophrenia-like psychosis.

To review the association between DWS and psychosis, we carried out a search on the MEDLINE database using the terms [(Psychosis OR Schizophrenia) AND Dandy-Walker], in all fields, without filter restrictions.

The initial search generated 17 articles, of which 12 were included in the review, while the other 3 were discarded due lack of relevance or unavailability. Searching the references of these articles, we found three additional studies. A total of 15 articles, reporting 19 patients, were included in the review.

Fifty-three percent of the patients were female. The mean age of onset of psychosis was 23 years. Dandy-Walker variant was the subtype more frequently associated with psychosis. Additional psychiatric comorbidities, such as obsessive-compulsive disorder, post-traumatic stress disorder or mania, were described in some of the cases. Atypical antipsychotics were the main treatment for psychosis in most of the cases reviewed. Complete results are shown in [table 1](#).

A coincidental association between DWS and psychosis cannot be ruled out. However, the high number of cases of comorbidity reported, considering the rareness of the condition, suggests a causal relationship.

DWS may cause psychosis via its cerebellar alterations, which may explain why Dandy-Walker variant, characterised by vermian hypoplasia, is the subtype more strongly associated with psychosis, despite being the milder condition of the group. Some studies have shown a smaller vermian volume and other cerebellar alterations in patients with schizophrenia.<sup>22–25</sup> According to the model proposed by Andreasen *et al*, psychotic symptoms may be the result of a dysfunction in the circuit connecting prefrontal, thalamic and cerebellar areas, a neurodevelopmentally derived ‘misconnection syndrome’ that would result in ‘cognitive dysmetry’, which has been described as a difficulty in prioritising, processing, coordinating and responding to information. According to this, a ‘poor mental coordination’ may explain both the cognitive deficits of schizophrenia and the wide range of symptoms. They opined that a decrease in the Purkinje cell size and decreased excitatory input to them from the granule cells have major implications that explain cerebellar and corticocerebellar–thalamic–cortical circuit dysfunction in schizophrenia and related abnormalities in symptoms and cognition.<sup>21</sup> We think that these findings could predispose the occurrence of the other mentioned psychiatric disorders ([table 1](#)).

In conclusion, this case report provides further evidence linking DWS with psychosis. Considering these findings, some clinical features seem to be common in this kind of psychosis: earlier age of onset, higher prevalence of treatment resistance and frequent comorbid intellectual disability. One of the challenges that this condition poses is that of differentiating which symptoms are related to psychosis and which are caused by the primary neurological condition, especially in the case of intellectual disability, since it can often

**Table 1** Articles that include cases report of DWS with comorbidity with psychiatry symptoms

Study	Patient's sex and age (years)	Dandy-Walker subtype	Psychotic symptoms	Other psychiatric comorbidities	Age of onset of psychosis	Last antipsychotic medication used	Outcome
Kvitvik Aune <i>et al</i> <sup>3</sup>	Male, 22	Dandy-Walker variant	Auditory and visual hallucinations, persecutory delusions, blunted affect	Borderline intelligence (IQ=79)	12	Risperidone 2 mg/24 hours	Remission of positive symptoms, negative symptoms remained
Blaettner <i>et al</i> <sup>4</sup>	Male, 19	Dandy-Walker variant	Persecutory delusions, delusions of reference	OCD	17	Ziprasidone 120 mg/24 hours	Partial remission
Buonaguro <i>et al</i> <sup>5</sup>	Female, 29	DWS	Persecutory delusions, blunted affect, agitation episodes		20	Haloperidol 4 mg/24 hours	No response to treatment
Ferentinos <i>et al</i> <sup>6</sup>	Female, 21	Mega cisterna magna	Auditory hallucinations, persecutory delusions	Intellectual disability	18	Amisulpiride 1200 mg/24 hours	57% decrease in PANSS score (after treatment resistance with previous antipsychotics)
Gan <i>et al</i> <sup>7</sup>	Female, 15	Dandy-Walker malformation	Auditory hallucinations, delusions of persecution and control, abulia	Intellectual disability	11	Risperidone 4 mg/24 hours	39–76 decrease in the Scale for the Assessment of Positive Symptoms score, negative symptoms remained
Gan <i>et al</i> <sup>7</sup>	Male, 13	Dandy-Walker variant	Delusions of reference and persecution, blunted affect	Obsessive worries and school phobia	13	Quetiapine 400 mg/24 hours	50% reduction in BPRS (from 43 to 25) but recurrence because of discontinuation of the treatment
Gan <i>et al</i> <sup>7</sup>	Male, 45	Mega cisterna magna	Auditory hallucinations, delusions of persecution and jealousy	Borderline intelligence and memory impairment	32	Risperidone 7 mg/24 hours	34–56 decrease in BPRS, 4–6 decrease in the Clinical Global Impression of Severity scale core
Gan <i>et al</i> <sup>7</sup>	Male, 20	Posterior fossa arachnoid cyst	Delusions, stereotyped thinking	Borderline intelligence (IQ=69), hypomanic episode	20	Olanzapine 20 mg/24 hours	Full remission
Kumar <i>et al</i> <sup>8</sup>	Female, 37	Mega cisterna magna	Auditory and visual hallucinations, Catatonia.		31	Risperidone 4 mg/24 hours	Partial remission
Langarica nd Peralta <sup>9</sup>	Female, 52	Mega cisterna magna	Persecutory and reference delusions		52	Olanzapine 7.5 mg/24/hours	Significant clinical improvement
Mauritz <i>et al</i> <sup>10</sup>	Female, 47	Dandy-Walker malformation		PTSD	47	Quetiapine 600mg – 1000mg/24 hours	Full remission
Pandurangi <i>et al</i> <sup>11</sup>	Male, 26	Megacisterna magna	Delusions of grandiosity	Mania	26	Risperidone 4 mg/24 hours	Significant clinical improvement, delirious and urinary incontinence as secondary effects
Pandurangi <i>et al</i> <sup>11</sup>	Male, 20	Megacisterna magna	Catatonia		18	Risperidone 3 mg/24 hours	Discontinuation of treatment due to acute dystonia

Continued

Table 1 Continued

Study	Patient's sex and age (years)	Dandy-Walker subtype	Psychotic symptoms	Other psychiatric comorbidities	Age of onset of psychosis	Last antipsychotic medication used	Outcome
Papazisis <i>et al</i> <sup>12</sup>	Male, 20	Dandy-Walker variant	Delusions	OCD	20		No response to treatment
Ryan <i>et al</i> <sup>13</sup>	Female, 14	Dandy-Walker variant	Auditory hallucinations, paranoid delusions		14	Risperidone 2.25 mg/24 hours	Full remission
Sidana <i>et al</i> <sup>14</sup>	Male, 20	Dandy-Walker variant	Auditory hallucinations, social withdrawal.		20	Aripiprazol 2.5 mg/24 hours	Significant clinical improvement, increase sensitivity to extrapyramidal side effects
Turner <i>et al</i> <sup>15</sup>	Female, 18	Dandy-Walker variant	Auditory hallucinations, paranoid delusions, conceptual disorganisation		18	No medication	Significant clinical improvement
Williams <i>et al</i> <sup>16</sup>	Female, 20	Dandy-Walker variant	Auditory hallucinations, delusions of reference and telepathy, bizarre behaviour	Depression and anxiety	20	Paliperidone palmitate 150 mg/28 days	Significant clinical improvement (after treatment resistance with previous antipsychotics)
Bozkurt Zincir <i>et al</i> <sup>17</sup>	Female, 30	Dandy-Walker variant	Auditory and visual hallucinations, delusions of reference, persecution and control	Borderline intelligence (IQ=75)	28	Risperidone 50 mg/14 days	35% decrease in PANSS score (from 144 to 90)

BPRS, Brief Psychiatric Rating Scale; DWS, Dandy-Walker syndrome; OCD, obsessive-compulsive disorder; PANSS, Positive and Negative Syndrome Scale; PTSD, post-traumatic stress disorder.

be mistaken for negative symptoms. Additionally, the management of non-psychiatric complications of DWS can improve the patient's general well-being.

Despite the body of evidence linking schizophrenia to brain abnormalities, current Diagnostic and Statistical Manual of Mental Disorders, Fifth Edition, diagnostic criteria for schizophrenia exclude this diagnosis when symptoms are considered to be caused by a neurological condition. Thus, we must refer to this entity as schizophrenia-like psychosis, even if the rest of the criteria for schizophrenia are met. As research advances and the aetiology of schizophrenia become clearer, the boundary between primary and secondary schizophrenia may become blurrier.<sup>26 27</sup> Further research is needed to establish the prevalence and characteristics of psychotic symptoms in patients with DWS. This association may contribute to the understanding of the aetiopathogenesis of schizophrenia.

**Contributors** All the authors have been clinically involved in the planning, conducting, reporting, writing, reviewing and publishing of this case. The patient consented to publish this clinical case.

**Funding** The authors have not declared a specific grant for this research from any funding agency in the public, commercial or not-for-profit sectors.

**Competing interests** None declared.

**Patient consent for publication** Obtained.

**Provenance and peer review** Not commissioned; externally peer reviewed.

**Open access** This is an open access article distributed in accordance with the Creative Commons Attribution Non Commercial (CC BY-NC 4.0) license, which permits others to distribute, remix, adapt, build upon this work non-commercially, and license their derivative works on different terms, provided the original work is

properly cited, appropriate credit is given, any changes made indicated, and the use is non-commercial. See: <http://creativecommons.org/licenses/by-nc/4.0/>.

#### ORCID iDs

Margarita Guerrero-Jiménez <http://orcid.org/0000-0002-2162-167X>  
Luis Gutierrez-Rojas <http://orcid.org/0000-0003-0082-2189>

#### REFERENCES

- Klein JL, Lemmon ME, Northington FJ, *et al*. Clinical and neuroimaging features as diagnostic guides in neonatal neurology diseases with cerebellar involvement. *Cerebellum Ataxias* 2016;3:1.
- Sasaki-Adams D, Elbabaa SK, Jewells V. The Dandy-Walker variant: a case series of 24 pediatric patients and evaluation of associated anomalies, incidence of hydrocephalus, and developmental outcomes. *J Neurosurg* 2008;2:194-9.
- Kvitvik Aune I, Bugge E. Schizophrenia in a young man with Dandy-Walker variant. *Biol Psychiatry* 2014;75:e9-10.
- Blaettner C, Pfaffenberger NM, Cartes-Zumelzu F, *et al*. Psychiatric misdiagnoses in Dandy-Walker variant. *Neurocase* 2015;21:499-500.
- Buonaguro EF, Cimmarosa S, de Bartolomeis A. Dandy-Walker syndrome with psychotic symptoms: a case report. *Riv Psichiatr* 2014;49:100-2.
- Ferentinos PP, Kontaxakis VP, Havaki-Kontaxaki BJ, *et al*. Refractory psychosis and prominent cognitive deficits in a patient with megacisterna MagNA. *Prog Neuropsychopharmacol Biol Psychiatry* 2007;31:561-3.
- Gan Z, Diao F, Han Z, *et al*. Psychosis and Dandy-Walker complex: report of four cases. *Gen Hosp Psychiatry* 2012;34:102.e7-102.e11.
- Kumar S, Sur S, Singh A. Mega cisterna MagNA associated with recurrent catatonia: a case report. *Biol Psychiatry* 2011;70:19.
- Langarica M, Peralta V. Psicosis asociada a megacisterna MagNA. *An Sist Sanit Navar* 2005;28:119-21.
- Mauritz MW, van de Sande R, Goossens PJJ, *et al*. Phase-based treatment of a complex severely mentally ill case involving complex posttraumatic stress disorder and psychosis related to Dandy Walker syndrome. *J Trauma Dissociation* 2014;15:588-606.
- Panduranghi S, Panduranghi A, Matkar A, *et al*. Psychiatric manifestations associated with mega cisterna MagNA. *J Neuropsychiatry Clin Neurosci* 2014;26:169-71.



- 12 Papazisis G, Mastrogianni A, Karastergiou A. Early-onset schizophrenia and obsessive-compulsive disorder in a young man with Dandy-Walker variant. *Schizophr Res* 2007;93:403–5.
- 13 Ryan M, Grenier E, Castro A, et al. New-onset psychosis associated with Dandy-Walker variant in an adolescent female patient. *J Neuropsychiatry Clin Neurosci* 2012;24:241–6.
- 14 Sidana A, Sarkar S, Balasundaram S, et al. Increased sensitivity to atypical antipsychotics in a patient with Dandy-Walker variant with schizophrenia. *J Neuropsychiatry Clin Neurosci* 2013;25:E31–2.
- 15 Turner SJ, Poole R, Nicholson MR, et al. Schizophrenia-like psychosis and Dandy-Walker variant. *Schizophr Res* 2001;48:365–7.
- 16 Williams AJ, Wang Z, Taylor SF. Atypical psychotic symptoms and Dandy-Walker variant. *Neurocase* 2016;22:472–5.
- 17 Bozkurt Zincir S, Kivilcim Y, Izci F, et al. Schizophrenia-Like psychosis and Dandy-Walker variant comorbidity: case report. *Psychiatry Investig* 2014;11:102–4.
- 18 Hesdorffer DC. Comorbidity between neurological illness and psychiatric disorders. *CNS Spectr* 2016;21:230–8.
- 19 Perez-Garcia CG. Erbb4 in laminated brain structures: a neurodevelopmental approach to schizophrenia. *Front Cell Neurosci* 2015;9:472.
- 20 Buoli M, Serati M, Caldiroli A, et al. Neurodevelopmental versus neurodegenerative model of schizophrenia and bipolar disorder: comparison with physiological brain development and aging. *Psychiatr Danub* 2017;29:24–7.
- 21 Andreasen NC, Pierson R. The role of the cerebellum in schizophrenia. *Biol Psychiatry* 2008;64:81–8.
- 22 Ichimiya T, Okubo Y, Suhara T, et al. Reduced volume of the cerebellar vermis in neuroleptic-naive schizophrenia. *Biol Psychiatry* 2001;49:20–7.
- 23 Martin P, Albers M. Cerebellum and schizophrenia: a selective review. *Schizophr Bull* 1995;21:241–50.
- 24 Neckelmann G, Specht K, Lund A, et al. Mr morphometry analysis of grey matter volume reduction in schizophrenia: association with hallucinations. *Int J Neurosci* 2006;116:9–23.
- 25 Zhang XY, Fan F-M, Chen D-C, et al. Extensive white matter abnormalities and clinical symptoms in drug-naive patients with first-episode schizophrenia: a voxel-based diffusion tensor imaging study. *J Clin Psychiatry* 2016;77:205–11.
- 26 Heckers S, Barch DM, Bustillo J, et al. Structure of the psychotic disorders classification in DSM-5. *Schizophr Res* 2013;150:11–14.
- 27 Kupfer DJ, Regier DA. Neuroscience, clinical evidence, and the future of psychiatric classification in DSM-5. *Am J Psychiatry* 2011;168:672–4.



*Alejandra Porrás-Segovia completed her medical training at the University of Granada in Spain. She has made four university degrees from the University of Alcalá de Henares in Mental Health Emergencies and Affective Disorders, University of Granada in Neuroscience and Pain, International University of Valencia in Third Generation Psychotherapies and University of La Rioja in Sanitary Management and Direction. Currently she is developing her PhD in Clinical Medicine and Public Health. She is also working as a psychiatrist specialist in the Virgen de las Nieves Hospital (Granada). Alejandra performed the specialization via Médico Interno Residente in psychiatry in the Granada Sur Clinical Management Area, working a posteriori in the Community Mental Health Unit in this area for a year. Her main research interests include clinical Neuroscience and Health.*